Multifocal Juvenile Osteochondritis Dissecans of the Knee: A Case Series

Jeffrey R. Backes, MD, Thomas C. Durbin, MD,*
Jared C. Bentley, MD,* and Kevin E. Klingele, MD†‡*

Purpose: This retrospective case series reports on a group of patients with multifocal juvenile osteochondritis dissecans (MJOCD) of the knee and discusses demographic data, lesion location, stage, and treatment results.

Methods: Records of patients identified with MJOCD of the knee at a single institution were retrospectively reviewed. Demographic, radiographic, and surgical results were recorded. Lesions were descriptively classified and lesions undergoing surgical treatment were staged. Results of operative and nonoperative treatment were recorded.

Results: Fifty-nine lesions were identified in 28 patients who met the inclusion criteria. There were 22 males (78%) and 6 females (21%). Average age was 11.8 years (males, 6 to 17; females, 10 to 14). Thirty-six (61%) lesions were on the medial femoral condyle (MFC), 19 (32%) on the lateral femoral condyle, 2 (3%) on the trochlea, 1 (2%) on the patella, and 1 (2%) on the anteromedial tibial plateau. Forty-four (74%) lesions required operative treatment. Of the 32 stable lesions managed surgically, 25 (78%) achieved healing with operative treatment. All 12 unstable lesions identified were managed surgically with 5 (41%) healed after the initial operation. Lesions located on the MFC had a significantly higher rate of healing (89%) compared with lateral femoral condyle lesions (37%) ($P < 0.0001$).

Conclusions: MJOCD of the knee defines a subset of patients with >1 identified lesion occurring in the same or the contralateral knee. Prevalence of MJOCD of the knee is unknown. A high percentage of these patients require surgical intervention with only one quarter of stable lesions healing with conservative treatment. Healing rates of stable lesions after surgery was nearly twice that of unstable lesions undergoing surgical intervention. Lesions located on the MFC healed at a statistically significant greater rate than other locations within the knee. Sex, age, and associated discoid menisci had no effect on healing prognosis.

Level of Evidence: Level IV—case series.

Key Words: multifocal juvenile osteochondritis dissecans, knee, lesion

From the *Mount Carmel Medical Center; †Nationwide Children's Hospital; and ‡Department of Orthopaedics, The Ohio State University, Columbus, OH.

None of the authors received financial support for this study.
The authors declare no conflicts of interest.

Reprints: Kevin Klingele, MD, Department of Orthopedics, Nationwide Children's Hospital, 700 Children's Drive Suite A2630, Columbus, OH 43205-2696. E-mail: kevin.klingele@nationwidechildrens.org.

(*J Pediatr Orthop* 2013;00:000–000)

Osteochondritis dissecans (OCD) is an acquired, potentially reversible cause of knee pain among skeletally immature patients. The etiology is uncertain, with inflammation, ischemia, microtrauma, and genetics as hypothesized causes.[1–4] The condition affects subchondral bone, with secondary effects on the overlying articular cartilage.[2,3,5,6] Classification of knee OCD can be based on patient age, location, radiographic and magnetic resonance imaging (MRI) findings, and intraoperative appearance. Distinguishing juvenile from adult forms based on distal femoral physis maturity carries significant prognostic implications, with better prognosis and healing potential in younger patients with open growth plates.[2,7–10]

Juvenile OCD (JOCD) is being diagnosed at an increasing rate, likely because of greater detection ability and increased participation in competitive sports at younger ages.[10–12] Exact prevalence of JOCD is unknown, with reports of between 15 and 29 cases per 100,000.[13,14] The highest rates are among patients aged between 10 and 15 years, with a male-to-female ratio of approximately 2:1.[3]

The "classic" knee OCD lesion is seen in the posterolateral aspect of the medial femoral condyle (MFC) and is involved in the majority of cases (70% to 80%).[1–5,15] Other locations reported include the lateral femoral condyle (LFC) (15% to 20%), patella (5% to 10%), and femoral trochlea (1%).[1–5,15] Multifocal juvenile osteochondritis dissecans (MJOCD) defines a unique subset of patients with >1 lesion occurring in the same or the contralateral knee (Fig. 1A). This entity is poorly documented in the literature. Most case series of knee JOCD report bilateral knee lesions in approximately 15% to 30% of cases, however, the exact prevalence of multiple lesions in a single knee has never been reported.[3,8,11] The purpose of this retrospective case series is to report on 29 patients with MJOCD of the knee and discuss their demographic data, lesion location, stage, and treatment results.

METHODS

Following Institutional Review Board approval, records of patients identified with MJOCD of the knee between August 2004 and February 2011 at a single institution were retrospectively reviewed. Inclusion criteria

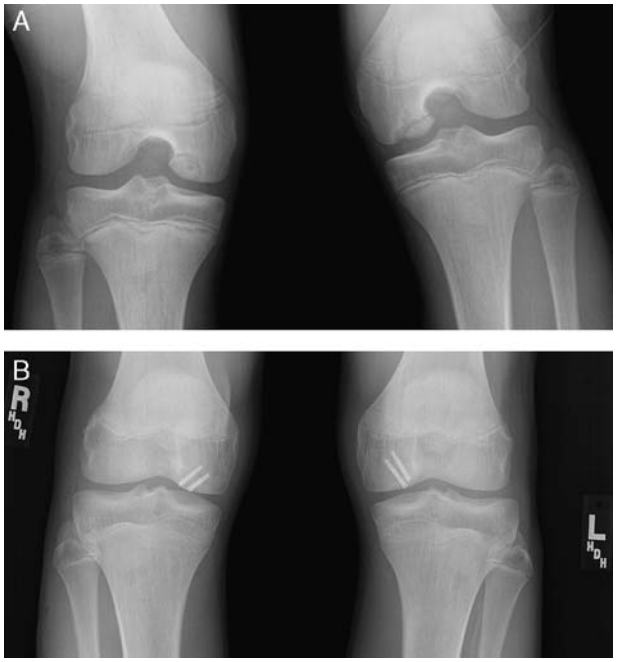

FIGURE 1. Preoperative tunnel knee radiograph (A) demonstrating bilateral lesions present on the posterior, lateral aspect of both medial condyles. Tunnel view radiograph (B) obtained 6 months postoperatively, revealing bilateral, healed osteochondritis dissecans lesions following arthroscopic in situ drilling and screw fixation. The patient was also asymptomatic and returned to sport without restriction, therefore, considered *healed* in our study.

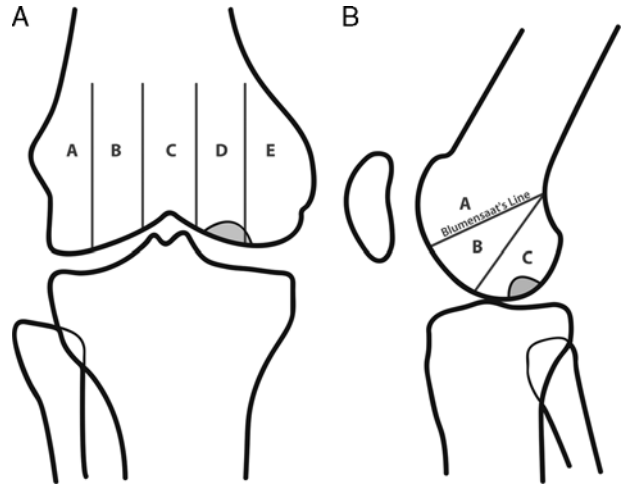

FIGURE 2. Classification of lesion location as described by Cahill and Berg.[6] A, Anterior projection; (B) lateral projection.

included any skeletally immature patient with >1 OCD lesion within a single knee or both knees as seen on MRI. All lesions were initially individually evaluated with anteroposterior, lateral, Merchant, and tunnel radiographs. The descriptive classification developed by Cahill and Berg[6] was used to define lesion location (Fig. 2). Lesions located in anteroposterior (Fig. 2A) areas A and B were considered LFC, those in areas D and E were considered MFC, and those in area C were considered trochlear lesions. From a lateral view (Fig. 2B), lesions in the A region were considered non–weight-bearing (NWB), and lesions in the B and C regions were considered weight-bearing (WB). An MRI was also obtained on all patients to evaluate the status of the cartilage and bone, and the presence of a retrograde, high-signal zone. "Stable" lesions were defined according to Dipaola et al[16] as lesions with either no break in articular cartilage (grade 1) or a nondisplaced cartilage breach/fracture with a low-signal rim behind the fragment indicating fibrous attachment (grade 2). High-signal T2 changes behind the fragment (grade 3) and loose bodies (grade 4) were defined as "unstable."

All "stable" lesions were initially treated with nonoperative management, consisting of a 6-week period of crutch-protected, toe-touch WB, and activity restriction. If the patient was pain free at the end of this period with no interval worsening on repeat radiographs, WB was advanced. Low-impact activities such as swimming and biking were allowed, but running, jumping, and cutting activities were prohibited for a minimum of 4 to 6 months. Asymptomatic patients with radiographs demonstrating disappearance of the radiolucent zone of the OCD at 4- to 6-month follow-up were cleared to return to sport.

Operative treatment was performed on patients unresponsive to nonoperative management and in those with detached or "unstable" lesions. In patients who had both stable and unstable lesions concominantly in an ipsilateral knee, surgical management was based on arthroscopic findings on an individualized basis. Standard surgical interventions were performed by the senior author: (1) retrograde, in situ drilling for lesions with intact articular cartilage; (2) retrograde, in situ drilling with screw fixation for unstable lesions with subchondral bone attached and an anatomic match between the deficit and fragment; (3) microfracture for large unsalvageable fragments; (4) and autologous chondrocyte implantation (Carticel, Genzyme Biosurgery, Cambridge MA) or osteochondral allograft for salvage of full-thickness defects that failed initial surgical intervention.

A minimum of 12-month follow-up from initial presentation was required for inclusion. To be considered "healed," patients must have been asymptomatic, returned to sport without restrictions, and demonstrated the disappearance of the radiolucent zone or union of the displaced fragment on follow-up plain films (Fig. 1B). Lesions that were treated with microfracture techniques and met the above criteria were considered healed acknowledging that the native hyaline cartilage was reconstituted with fibrocartilage. Patients with continued symptoms, persistent evidence of a radiolucent zone on plain films, or those requiring any further operative intervention were considered "failures." Exclusion criteria included patients with closed physis, incomplete radiographic or clinical data, <12-month follow-up from initial presentation, osteochondral fractures related to trauma, concomitant patellar dislocations, and associated ligamentous injury.

The Generalized Linear Model (GENMOD) procedure[17] with repeated statement[18] was used to assess for correlation within subjects. Briefly, a GENMOD is a form of regression analysis that extends the traditional linear model to be applicable to a wider range of data analysis problems, enabling the authors to account for the effects of multiple measures from single subjects.[17,19] Repeated measures logistic regression was used to test the effect of sex, age, lesion location, lesion grade, associated discoid anatomy, and treatment on outcome (healed vs. failed). Four distinct treatments: nonoperative, in situ drilling, screw fixation, and microfracture were included as independent predictors in each bivariate model. All tests were conducted in SAS 9.3 (SAS Institute Inc., Cary, NC), with $P < 0.05$ to be considered significant.

RESULTS

There were 34 consecutive patients with a total of 69 OCD lesions identified. Three patients (6 OCD lesions) were excluded because of <12-month follow-up, 1 patient (2 OCD lesions) was excluded for incomplete radiographic data (outside MRI not available for review), and 1 patient (2 OCD lesions) for concomitant patellar dislocation. This resulted in a total of 28 patients and 59 OCD lesions. There were 22 males (47 OCD lesions) and 6 females (12 OCD lesions) included. Mean patient age was 11.8 (range, 6 to 17 y). Thirty-one lesions were located in the right knee (52.5%) and 28 were in the left knee (47.5%). Of the 28 patients included, 7 patients had multiple lesions unilaterally, with 21 patients having lesions in bilateral knees. There were 3 patients with 3 lesions, whereas the remaining all had 2 lesions each.

Thirty-six OCD lesions (61%) were located on the MFC, 19 on the LFC (32%), 2 on the trochlea (3.4%), 1 on the patella (2%), and 1 on the anteromedial tibia (2%). Table 1 shows the breakdown of treatment and healing rates on the basis of lesion location. Fifty-three lesions (90%) were located in the WB areas and 4 (7%) in the NWB area. A discoid meniscus was present with 10 lesions (6 on the LFC and 4 on the MFC).

On the basis of MRI assessment, there were 47 stable lesions (80%) and 12 unstable lesions (20%) (Fig. 3). Twelve stable lesions (10 patients) healed following conservative management; therefore, 12 of 47 stable lesions (26%) were successfully managed nonoperatively. Thirty-two lesions (21 = grade 1; 11 = grade 2) initially classified as stable on MRI underwent surgical intervention after an unsuccessful conservative trial. Of those 32 lesions, 25 healed after surgical treatment (78.1%). The 7 failures included 2 with persistent radiographic evidence of a lesion, and 5 that required further surgical procedures. Three additional stable lesions failed nonoperative treatment and refused any further intervention. These patients were considered "failures" of nonoperative treatment by our definition: 2 continued to be symptomatic, and 1 demonstrated persistent radiographic evidence of the lesion.

Twelve unstable lesions (3 = grade 3; 9 = grade 4) were identified on presentation and were treated surgically. Of those 12 unstable lesions, 5 healed after the initial operation (42%). The 7 failures included 3 with persistent symptoms and 4 that required further surgical intervention. Overall, of the 44 lesions (32 stable and 12 unstable) that underwent surgical intervention, 30 (68%) healed, whereas 14 (32%) failed initial surgical treatment. Figure 4 shows healing outcomes of the 44 surgically treated OCD lesions by arthroscopic grade and lesion location.

MFC lesions had a significantly higher rate of successfully healing when compared with LFC lesions ($P < 0.0001$). Of the 36 MFC lesions 32 (89%) went on to heal versus 7 of the 19 LFC lesions (37%). Table 1 shows healing rates for MFC and LFC lesions based on treatment. Thirty-eight of 53 lesions in WB areas healed (72%) versus 2 of 4 lesions in the NWB area (50%). This difference was not significant ($P > 0.05$). Sex, age, or the presence of a discoid meniscus did not have a significant difference in the probability of healing. The presence of ipsilateral lesions was not an independent predictor of healing.

Both ipsilateral and bilateral OCD lesions have been characterized as "multifocal" in previous reports, and more commonly, a clear distinction between these findings is not made. Our review found 7 patients with >1 lesion in an ipsilateral knee (14 total lesions). On the basis of MRI assessment, 12 of these were stable (86%) and 2 were unstable (14%). As was true with lesions in contralateral knees, all management decisions were made on individual lesion assessment. Four of the 12 stable lesions (33%) were successfully managed nonoperatively. Seven stable lesions failed conservative measures and required an operation, with 5 of 7 healed after surgery (71%). Two lesions were unstable at presentation. Both failed their initial operation and required further surgical intervention. The 2 high-grade, unstable lesions occurred on the LFC and were accompanied by a stable lesion on the ipsilateral MFC. Both MFC lesions were individually. In both patients, the stable MFC lesion healed after retrograde drilling.

TABLE 1. AP Location and Healing

Lateral "B" = 7/19 Healed*	Medial "D" = 32/36 Healed*
Nonsurgical = 3/6 healed	Nonsurgical = 7/7 healed
In situ drill = 2/5 healed	In situ drill = 17/17 healed
Screw = 0/2 healed	Screw = 6/7 healed
Micro fx = 2/6 healed	Micro fx = 2/5 healed

*Healing rates between osteochondritis dissecans lesions located on the medial femoral condyle were significantly better than lesions on the lateral femoral condyle ($P < 0.0001$).

DISCUSSION

The prevalence of multifocal juvenile osteochondral dissecans of the knee is unknown. Bilateral knee involvement has been reported to exist in 13% to 30% of juvenile patients with OCD lesions, but outcome data and even lesion characteristics are lacking in these studies.[2–4,8,11,21–28] The large, multicenter review of the

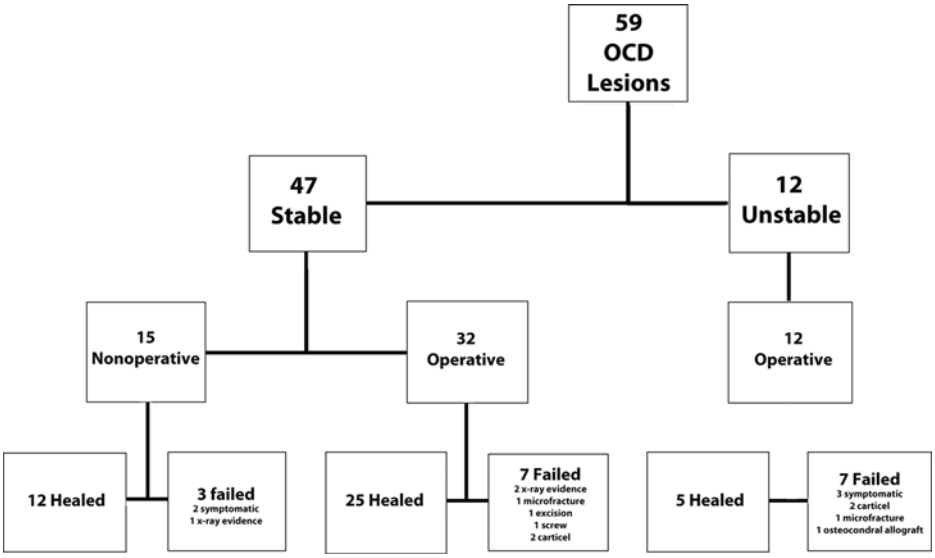

FIGURE 3. Healing rates of all osteochondritis dissecans (OCD) lesions organized by lesion stability as assessed by magnetic resonance imaging.[16] To be considered healed the patient must be asymptomatic, returned to sport without restrictions, and demonstrated the disappearance of the radiolucent zone or union of the displaced fragment on follow-up plain films.

European Pediatric Orthopedic Society by Hefti et al[8] reported bilateral involvement in 13% of patients, but failed to mention specific lesion location in this subset of patients. The recently released AAOS Clinical Practice Guidelines for Diagnosis and Treatment of Osteochondritis Dissecans reported an inability to find evidence to support or recommend obtaining contralateral knee radiographs.[26] However, based on prior reports and our current case series, assessment of both knees is critical when evaluating a patient with suspected or confirmed OCD of the knee. Lesions are often in different phases of development and despite an asymptomatic presentation or examination, radiographic assessment of both the knees should be conducted.

The classic location of OCD lesions in the knee is the lateral aspect of the MFC, involved in 70% to 80% of cases.[1–5,8,15] The LFC has been reported to be involved in 15% to 17% of cases, with patellar involvement (5% to

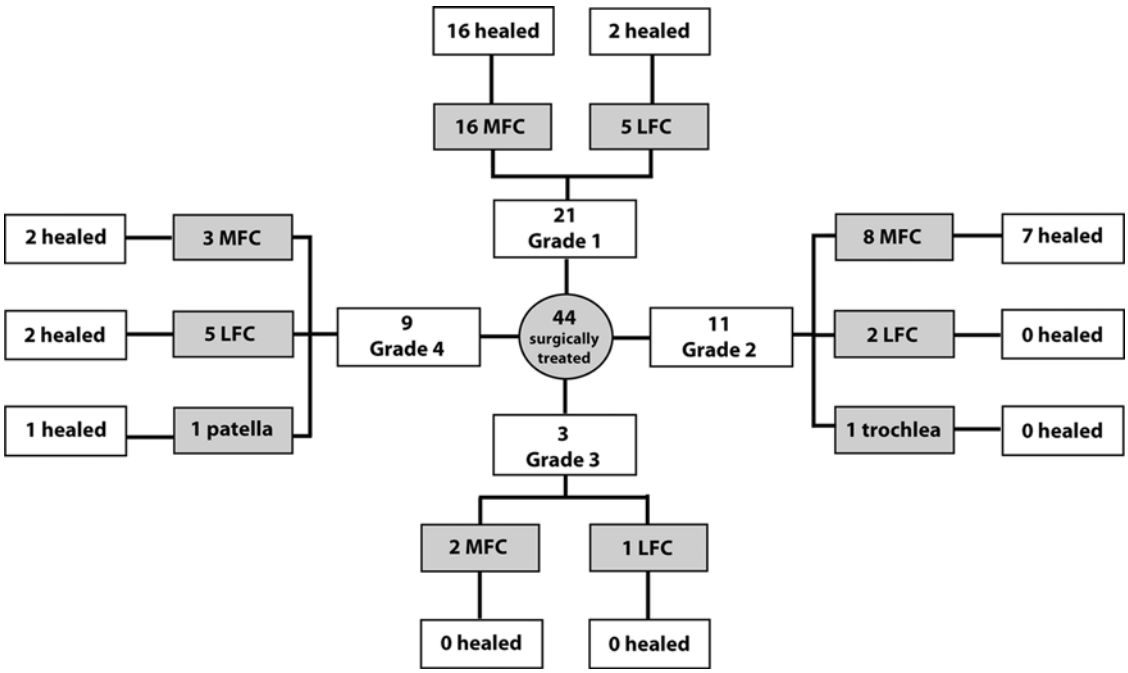

FIGURE 4. Distribution of surgically treated osteochondritis dissecans (OCD) lesions by arthroscopic grade[20] and lesion location. LFC indicates lateral femoral condyle; MFC, medial femoral condyle.

8%) and femoral trochlear lesions (1%) much less common.[1–4] Our case series had a higher rate of LFC lesions (32%) than most previous reports of juvenile OCD. The association between lesion location and prognosis is inconsistent in the literature. Hefti et al[8] found a better prognosis in association with classic MFC lesions as compared with other sites. Others have found that nonmedial femoral condylar lesions are associated with a better prognosis and that coronal plane location has no influence on healing.[27,28] We found a statistically significant higher rate of healing for MFC lesions (89%) versus LFC lesions (37%) ($P < 0.001$). However, LFC lesions were more likely to be unstable than MFC lesions (32% vs. 14% respectively).

Aichroth et al[12] showed as association between discoid lateral meniscus and the less common LFC lesion. Although LFC lesions were more likely to be associated with a discoid meniscus in the same compartment in our study population ($P < 0.05$), the presence of a discoid meniscus did not affect healing. This was true across all treatment types.

Surprisingly, our results demonstrated no significant effect of age on healing prognosis. Wall et al[29] assessed healing potential of stable JOCD lesions and also found that age did not affect radiographic healing rates; however, the majority of literature reports younger age to be an independent predictor of healing rates, both in stable and unstable lesions.[2,3,5,13] Nonoperative management is well described for JOCD lesions, and is often a reliable method for young patients with stable lesions. Linden[30] reported excellent results with conservative management of JOCD lesions, and others have reported healing rates of nearly 95%.[29] Others, however, demonstrated successful healing rates of only 50% after a period of 6 to 18 months of nonoperative treatment.[9,10,28] While all lesions in our study considered stable on initial MRI underwent a trial of nonoperative management, only 12 of the 47 lesions (25.5%) healed with conservative management. Although there was an obvious trend for stable lesions treated surgically to heal more reliably compared with unstable lesions treated surgically (25/32 vs. 5/12, respectively), this difference was not significant ($P = 0.1374$). Multiple lesions has been listed in prior studies as a factor associated with inadequate healing,[1] but it is difficult to compare our population of all MJOCD with healing rates from studies consisting predominately of single-lesion patients. Further studies are needed to determine if our lower than expected healing rates after conservative management are a result of multifocal lesions. The implication that patients with MJOCD are less successful with nonoperative treatment could help guide treating physicians to intervene earlier when multiple OCD lesions are identified.

A major limitation of the present study is the heterogeneity of this pathology. Lesion size was not accurately documented for all patients in our study. Several authors have documented size parameters by which outcome is directly associated.[3,9,13] Furthermore, other variables such as number of loose fragments, the presence and reparability of bone associated with each chondral fragment, and the quality of the underlying subchondral bone when visualized were not directly compared and are all important factors in determining outcomes. While the majority of patients had 1 lesion in each knee, there were 7 patients with ipsilateral lesions. For statistical purposes, each lesion was individually analyzed. While the healing rates of ipsilateral lesions were not statistically different from those of contralateral lesions in our study population, to assess each lesion independently may have ignored certain variables that effect outcome.

There is no current standard by which to evaluate or characterize "healing" of an OCD lesion. The works of Edmonds and others[20,30,31] suggest that healing can be evaluated by serial radiography however, Parikh[32] demonstrated poor reliability between observers. In light of the insensitivity of radiographs, Cahill and Berg[6] recommended skeletal scintigraphy to evaluate healing despite its invasiveness and impracticality. MRI has become routine diagnostically given its accuracy of characterizing subchondral bone but is not feasible given its expense. Despite imprecise standards, plain films continue to be the imaging study of choice for follow-up[32] and hence were used in combination with clinical symptoms to evaluate healing in our study.

An important distinction in our study was characterizing OCD lesions as stable or unstable, as this was central to the treatment algorithm. We followed strict adherence to the MRI criteria of Dipaola, which was shown in 1 study to have an 85% correlation with arthroscopic findings.[3] A study from our institution, however, found agreement between MRI and arthroscopic grade to be only 62%.[33] Certainly incorrectly characterizing any lesions would alter our results.

CONCLUSIONS

MJOCD of the knee defines a subset of patients with >1 OCD lesion occurring in the same or the contralateral knee. Prevalence of MJOCD of the knee remains unknown. Our study population demonstrated only one quarter of patients with stable lesions healed following conservative management. Healing rates of stable lesions after surgery was nearly twice that of unstable lesions undergoing surgical intervention, with approximately 80% and 40% healing rates, respectively. Lesions located on the MFC healed at a statistically significant greater rate than other locations within the knee. Sex, age, and associated discoid mensci had no effect on healing prognosis.

REFERENCES

1. Polousky JD. Juvenile osteochondritis dissecans. *Sports Med Arthrosc*. 2011;19:56–63.
2. Flynn JM, Kocher MS, Ganley TJ. Osteochondritis dissecans of the knee. *J Pediatr Orthop*. 2004;24:434–443.
3. Crawford DC, Safran MR. Osteochondritis dissecans of the knee. *J Am Acad Orthop Surg*. 2006;14:90–100.
4. Schenck RC Jr, Goodnight JM. Osteochondritis dissecans. *J Bone Joint Surg Am*. 1996;78:439–456.

5. Kocher MS, Tucker R, Ganley TJ, et al. Management of osteochondritis dissecans of the knee: current concepts review. *Am J Sports Med*. 2006;34:1181–1191.
6. Cahill BR, Berg BC. 99m-Technetium phosphate compound joint scintigraphy in the management of juvenile osteochondritis dissecans of the femoral condyles. *Am J Sports Med*. 1983;11:329–335.
7. Green WT, Banks HH. Osteochondritis dissecans in children. *J Bone Joint Surg Am*. 1953;35-A:26–47; passim.
8. Hefti F, Beguiristain J, Krauspe R, et al. Osteochondritis dissecans: a multicenter study of the European Pediatric Orthopedic Society. *J Pediatr Orthop B*. 1999;8:231–245.
9. Cahill BR, Phillips MR, Navarro R. The results of conservative management of juvenile osteochondritis dissecans using joint scintigraphy. A prospective study. *Am J Sports Med*. 1989;17: 601–605; discussion 5-6.
10. Pill SG, Ganley TJ, Milam RA, et al. Role of magnetic resonance imaging and clinical criteria in predicting successful nonoperative treatment of osteochondritis dissecans in children. *J Pediatr Orthop*. 2003;23:102–108.
11. Cahill BR. Osteochondritis dissecans of the knee: treatment of juvenile and adult forms. *J Am Acad Orthop Surg*. 1995;3:237–247.
12. Aichroth PM, Patel DV, Marx CL. Congenital discoid lateral meniscus in children. A follow-up study and evolution of management. *J Bone Joint Surg Br*. 1991;73:932–936.
13. Hughston JC, Hergenroeder PT, Courtenay BG. Osteochondritis dissecans of the femoral condyles. *J Bone Joint Surg Am*. 1984;66:1340–1348.
14. Linden B. The incidence of osteochondritis dissecans in the condyles of the femur. *Acta Orthop Scand*. 1976;47:664–667.
15. Detterline AJ, Goldstein JL, Rue JP, et al. Evaluation and treatment of osteochondritis dissecans lesions of the knee. *J Knee Surg*. 2008;21:106–115.
16. Dipaola JD, Nelson DW, Colville MR. Characterizing osteochondral lesions by magnetic resonance imaging. *Arthroscopy*. 1991;7:101–104.
17. Hardin J, Hilbe J. *Introduction to General and Generalized Linear Models*. Boca Raton, FL: CRC Press; 2011.
18. Agresti A. A survey of models for repeated ordered categorical response data. *Stat Med*. 1989;8:1209–1224.
19. SAS. What is a generalized linear model? SAS. Available at: http://support.sas.com/documentation/cdl/en/statug/63033/HTML/default/viewer.htm#statug_genmod_sect002.htm. Accessed April 22, 2013.
20. Guhl JF. Arthroscopic treatment of osteochondritis dissecans. *Clin Orthop Relat Res*. 1982;167:65–74.
21. Cetik O, Turker M, Uslu M. Bilateral osteochondritis dissecans of lateral femoral condyle. *Knee Surg Sports Traumatol Arthrosc*. 2005;13:468–471.
22. Ghali A, James SL, Saifuddin A, et al. Bilateral osteochondrosis of the superior pole of the patellae in association with bilateral osteochondritis dissecans of the lateral femoral condyle. *Clin Radiol*. 2008;63:478–482.
23. Hashimoto Y, Yoshida G, Tomihara T, et al. Bilateral osteochondritis dissecans of the lateral femoral condyle following bilateral total removal of lateral discoid meniscus: a case report. *Arch Orthop Trauma Surg*. 2008;128:1265–1268.
24. Luessenhop S, Behrens P, Bruns J, et al. Bilateral osteochondritis dissecans of the medial trochlea femoris: an unusual case of patellofemoral pain. *Knee Surg Sports Traumatol Arthrosc*. 1993; 1:187–188.
25. Matsumoto H, Suda Y, Otani T, et al. Meniscoplasty for osteochondritis dissecans of bilateral lateral femoral condyle combined with discoid meniscus: case report. *J Trauma*. 2000;49: 964–966.
26. Mei-Dan O, Mann G, Steinbacher G, et al. Bilateral osteochondritis dissecans of the knees in monozygotic twins: the genetic factor and review of the etiology. *Am J Orthop (Belle Mead, NJ)*. 2009;38: E152–E155.
27. Moretti B, Notarnicola A, Moretti L, et al. A volleyball player with bilateral knee osteochondritis dissecans treated with extracorporeal shock wave therapy. *Chir Organi Mov*. 2009;93:37–41.
28. Takahashi Y, Nawata K, Hashiguchi H, et al. Bilateral osteochondritis dissecans of the lateral trochlea of the femur: a case report. *Arch Orthop Trauma Surg*. 2008;128:469–472.
29. Wall EJ, Vourazeris J, Myer GD, et al. The healing potential of stable juvenile osteochondritis dissecans knee lesions. *J Bone Joint Surg Am*. 2008;90:2655–2664.
30. Linden B. Osteochondritis dissecans of the femoral condyles: a long-term follow-up study. *J Bone Joint Surg Am*. 1977;59:769–776.
31. Edmonds EW, Polousky J. A review of knowledge in osteochondritis dissecans: 123 years of minimal evolution from König to the ROCK study group. *Clin Orthop Relat Res*. 2013;471:1118–1126.
32. Parikh SN, Allen M, Wall EJ, et al. The reliability to determine "healing" in osteochondritis dissecans from radiographic assessment. *J Pediatr Orthop*. 2012;32:e35–e39.
33. Samora WP, Chevillet J, Adler B, et al. Juvenile osteochondritis dissecans of the knee: predictors of lesion stability. *J Pediatr Orthop*. 2012;32:1–4.

