Trochlear Groove Osteochondritis Dissecans of the Knee Patellofemoral Joint

Eric J. Wall, MD, Benton E. Heyworth, MD,† Kevin G. Shea, MD,‡ Eric W. Edmonds, MD,§ Rick W. Wright, MD,‖ Allen F. Anderson, MD,¶ Emily A. Eismann, MS,* and Gregory D. Myer, PhD, FACSM, CSCS*D#*

Background: The trochlear groove is the rarest location for osteochondritis dissecans (OCD) of the knee, with only about 50 previously reported cases, most of which were treated before the advent of magnetic resonance imaging (MRI) and modern techniques of cartilage fixation or osteochondral transplantation. The purpose of this multicenter study was to assess the patient presentation and clinical, radiographic, and functional results of treatment for trochlear groove OCD lesions.

Methods: Hospital records from 5 institutions of the Research in Osteochondritis of the Knee (ROCK) study group were retrospectively reviewed for cases of trochlear groove OCD. Demographics, clinical presentation, diagnosis, treatment, time to pain resolution, and return to sports were recorded. Lesion appearance, size, stability, and time to radiographic healing were evaluated on plain x-rays and MRIs.

Results: Trochlear groove OCD lesions were evaluated in 24 knees in 21 adolescents (17 male, 4 female), with an average age of 14 years (range, 10 to 18 y). Fifty-four percent (13/24) of the lesions were identifiable on radiographs, and all were identifiable on MRI, 38% of which (9/24) was unstable. One fourth (6/24) of knees had coexistent femoral condyle OCD lesions. Treatment outcomes were evaluated in patients with a minimum of 1-year follow-up (average: 3 y; range: 1 to 12 y) or healing before 1 year. Half of the knees (2/4) treated nonoperatively and two thirds (8/12) treated operatively showed radiographic signs of healing with patients returning to full activity without pain. Operative treatment success rates were as follows: drilling (3/3), fixation (3/3), microfracture (1/2), drilling with subsequent delayed microfracture (1/1), and drilling with fixation (0/3).

Conclusions: MRI aids in the diagnosis and staging of trochlear groove OCD lesions, as almost one half may not be identifiable on radiographs, and one quarter are associated with OCD lesions in other locations of the same knee. Multiple operative treatments can be used to achieve healing or resolution of symptoms in stable and unstable lesions; however, a larger comparative study is needed to make specific recommendations.

Level of Evidence: Therapeutic Level IV.

Key Words: OCD, trochlea, patella, lesion, outcomes

(*J Pediatr Orthop* 2014;34:625–630)

The trochlear groove of the patellofemoral joint is the rarest location in the knee for osteochondritis dissecans (OCD) and accounts for 0.6% of all OCD knee lesions.[1,2] At present, little is known about the etiology and effectiveness of treatments for OCD lesions of the trochlear groove.[3,4] The diagnosis and treatment of trochlear groove OCD may differ from the standard location OCD of the femoral condyles because of the unique forces imparted on the surface of the patellofemoral joint. Approximately 50 cumulative cases of trochlear groove OCD have been reported in the literature, consisting of mostly small series and case reports.[1,5–10]

The American Academy of Orthopaedic Surgeons has created clinical practice guidelines for standard location OCD,[3,4] but these guidelines do not apply to trochlear groove OCD. Magnetic resonance imaging (MRI) has revolutionized the evaluation and treatment of standard location OCD, but its utility for trochlear groove OCD has not been reviewed.[3,4] Because the most likely cause of OCD in young athletes is believed to be a chronic, repetitive stress injury,[11–15] the nonoperative treatment for standard location OCD generally involves sports cessation and unweighting the knee with crutches, an unloader brace, or cast/brace immobilization. Nonoperative treatment of standard location OCD reportedly leads to healing in up to 2/3 of patients with open growth plates,[16] but the nonoperative success rate is largely unknown in trochlear groove OCD. As the patellofemoral joint is under greater load produced by different forces when compared with the femoral condyles,[17–25] nonoperative treatment may be less effective for trochlear groove OCD. Many contemporary treatments using arthroscopic and open operative techniques, such as fixation, drilling, and microfracture, have been successful in treating standard location OCD but have not been evaluated in patients

From the Divisions of *Orthopaedic Surgery; #Sports Medicine, Cincinnati Children's Hospital, Cincinnati, OH; †Department of Orthopedic Surgery, Division of Sports Medicine, Boston Children's Hospital, Boston, MA; ‡St. Luke's Intermountain Orthopaedics, Boise, ID; §Division of Orthopaedic Surgery, Rady Children's Hospital, San Diego, CA; ‖Department of Orthopaedic Surgery, Washington University School of Medicine, St. Louis, MO; and ¶Tennessee Orthopaedic Alliance, Nashville, TN.

The authors declare no conflict of interest.

Reprints: Eric J. Wall, MD, Division of Orthopaedic Surgery, Cincinnati Children's Hospital, 3333 Burnet Avenue, MLC 2017, Cincinnati, OH 45229. E-mail: eric.wall@cchmc.org.

with trochlear groove OCD. Prior studies have focused primarily on nonoperative treatments or operative fragment excision, which have shown varying success rates in relieving pain and returning adolescents to full activities.[1,5–10] The outcome measures used in prior studies are also variable, preventing comparison of healing rates between different treatments.[1,5–10]

The purpose of this multicenter study was to describe the clinical and radiographic presentation, diagnosis, treatment, and clinical outcomes in a large sample of adolescents with an OCD lesion located in the trochlear groove of the knee patellofemoral joint. The outcomes of radiographic healing, pain resolution, and return to full activity were also assessed for different treatments.

METHODS

Study Design

This multicenter, retrospective study included patients between 10 and 18 years of age with a diagnosis of OCD of the trochlear groove of the knee patellofemoral joint. A convenience sample of patients was identified by searching hospital records at 5 of the 13 institutions in the Research in Osteochondritis of the Knee (ROCK) group, which is a self-funded research study group formed in 2009. All 5 institutions obtained approval from their Institutional Review Boards before sharing cases. Inclusion criteria required the OCD lesion to be located in the trochlear groove, as confirmed on MRI, and defined as involving a portion of the femoral joint surface that articulates with the patella.

Clinical and Radiographic Measures

Medical records were reviewed for demographic information (eg, age, sex, sports participation, activity level, and family history), duration of symptoms before clinical presentation, symptoms (eg, mechanical locking, catching, swelling, pain), physical examination information (eg, tenderness, effusion), and treatment. Plain x-rays were reviewed by an investigator at each patient's respective site to assess healing of the lesion in response to treatment. Healing was defined as new bone formation (reossification) of the lesion across a sequence of anteroposterior, lateral, sunrise, and notch/tunnel x-rays. If the OCD lesion was not visible on plane x-ray, then MRI or computed tomography scan was used to assess healing. MRI was also used to assess the size, shape, and stability of the lesion, based on the criteria described by Hefti et al.[26] "Success" of treatment, by our definition, required all 3 criteria to be met for lesions undergoing drilling or fixation, and the latter 2 criteria for cases of lesion debridement/excision with "resurfacing" techniques (eg, microfracture): (1) healing on imaging studies, (2) full return to activities, and (3) pain resolution. "Failure" of treatment was defined as either no progression toward healing on imaging studies, inability to return to sports, or continued pain.

Data Analysis

Descriptive statistics were utilized to characterize the clinical presentation, diagnosis, treatment, and clinical and radiographic outcomes of the patient sample.

RESULTS

Sample Characteristics

OCD lesions were identified in the trochlear groove of 24 knees in 21 patients (17 males, 4 females) from 5 institutions. Of the 21 patients, 3 (14%) had bilateral trochlear groove OCD lesions. The average age at presentation was 14 ± 2 years (n = 21; range, 10 to 18 y). All but one patient (95%, 20/21) played sports at baseline. The most common sports played were basketball, football, and soccer, and 7 patients (33%) played ≥ 2 sports. Symptoms began at an average of 6 ± 11 months (n = 18; range, 0.5 to 36 mo) before clinical presentation to one of the centers involved in the study.

Diagnosis and Clinical Presentation

At presentation, 94% (17/18) of patients reported pain, 39% (7/18) swelling, 28% (5/18) popping, 22% (4/18) locking, and 17% (3/18) catching. The majority of patients (67%, 12/18) reported having ≥ 2 symptoms at presentation. Clinical examination showed tenderness in 59% (10/17) of patients and effusion in 35% (6/17). A trochlear OCD lesion was detected at presentation on only 13 of the 24 knee radiographs (Fig. 1). One of the 13 knees with positive radiographs had subtle findings only seen in hindsight. MRI was available for review for all patients (Fig. 2). Twelve of the MRIs reviewed showed a stable OCD: 3 were indeterminate and 9 MRIs showed signs of instability, with chondral findings ranging from subtle cartilage fissuring to gross lesion separation (Fig. 3). In addition to radiographs and MRIs, 1 patient underwent a computed tomography scan to evaluate the amount of bone in the OCD lesion (Fig. 4). On the basis of the radiographs and MRIs, 75% of knees (18/24) had isolated trochlear groove lesions. Femoral condyle OCD lesions were identified in the ipsilateral knee of 5 patients (24%, 5/21; 3 medial, 2 lateral) and the contralateral knee of 5 patients (24%, 5/21; 4 medial, 1 lateral). Four of these patients had bilateral femoral condyle OCD lesions, one of which had bilateral trochlear groove OCD lesions.

Clinical and Radiographic Outcomes

Fifteen patients (16 knees) had either a minimum of 1 year follow-up (n = 8; mean = 3.0 ± 3.7 y; range, 1 to 12 y) or healed before one year (n = 7). Of the 4 patients who underwent nonoperative treatment initially, 2 (50%) patients—one treated with activity restriction and another with physical therapy—showed radiographic signs of healing and fully returned to activities without complaints of pain by 9 months (Table 1). One patient treated with activity restriction had issues with compliance and showed worsening of the lesion on MRI after 1 and a half years. Another patient treated with casting/bracing and activity restriction went on to operative treatment,

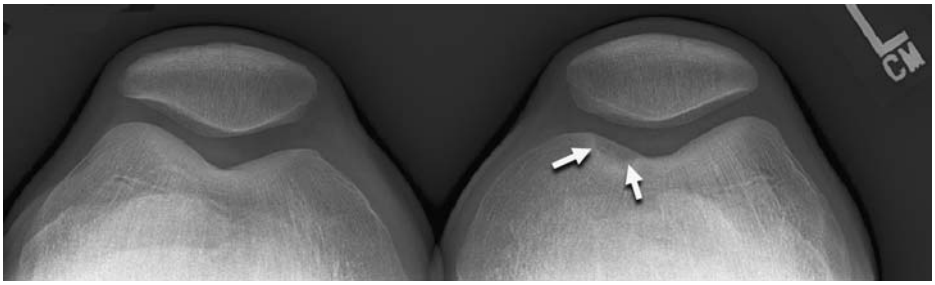

FIGURE 1. A bilateral radiographic sunrise view showing an osteochondritis dissecans lesion (arrows) in the medial trochlear groove of the left knee.

specifically subchondral bone drilling, and healed with full return to activities and no pain by 2 years.

Of the 12 knees that underwent operative treatment, 8 (67%) showed radiographic healing with the patients returning to full activities and no complaints of pain (Table 1). All 3 patients treated with internal fixation (2 stable, 1 unstable lesion) and all 3 patients treated with subchondral bone drilling (all stable lesions, retroarticular drilling with grafting in one) demonstrated healing. Two patients (one with bilateral trochlear groove OCD) were treated with internal fixation and subchondral bone drilling (all stable lesions) and continued to have pain, with one being healed on radiographs but not released to full activities and the other being released to full activities but not healed on radiographs. One patient with an unstable lesion who was treated with primary chondral debridement and microfracture showed reossification of the involved subchondral bone by 8 months, whereas another patient with an unstable lesion treated with primary chondral debridement and microfracture continued to have pain without full return to activities up to 1 year. An additional patient with an unstable lesion was treated with subchondral bone drilling with later debridement and microfracture showed reossification of the involved subchondral bone on radiographs after 2 months.

FIGURE 2. Magnetic resonance image showing an osteochondritis dissecans lesion (arrows) in the trochlear groove of the knee.

DISCUSSION

This multicenter study evaluated 24 knees containing OCD lesions of the trochlear groove from 21 adolescents between 10 and 18 years of age from 5 institutions within the United States. Only about half (54%) of the trochlear groove lesions were identified on radiographs. All lesions were identifiable on MRI, with 38% being unstable and 25% of knees containing a lesion in the femoral condyles as well. Trochlear groove OCD lesions were predominantly found in males (81%) and athletes (95%). Patients with OCD lesions of the trochlear groove presented to the study clinicians at an average of 6 months after their symptoms began, with some patients presenting after 2 to 3 years of symptoms. Most patients presented with pain (94%) and tenderness (59%) in the knee. Swelling (39%), popping (28%), locking (22%), and effusions (35%) were also common. Half (2/4) of the nonoperatively treated knees and 67% (8/12) of the operatively treated knees showed radiographic signs of healing and returned to full activity without pain.

Although OCD is most commonly located in the medial femoral condyle of the knee,[12,14,24,25] a few reports have described lesions of the patellofemoral joint.[27–31] These case reports and small series[1,5–10,32–34] provide context for the current study. The average age of patients in this study was 14 years, which is lower than other studies[7] and may reflect the fact that most of the cases came from pediatric institutions. Almost all patients (95%) in the study participated in sports, most at a high level, which supports an association of trochlear groove lesions with athletics and a likely etiology of repetitive microtrauma, or an overuse phenomenon.

Unlike prior series on trochlear groove OCD,[8] in most of our cases, MRI was utilized as part of their initial clinical examination. MRI findings of instability were often confirmed on arthroscopy, with 9 of 24 knees showing instability at presentation. This rate is substantially higher than that reported for OCD lesions occurring in the standard location of the medial femoral

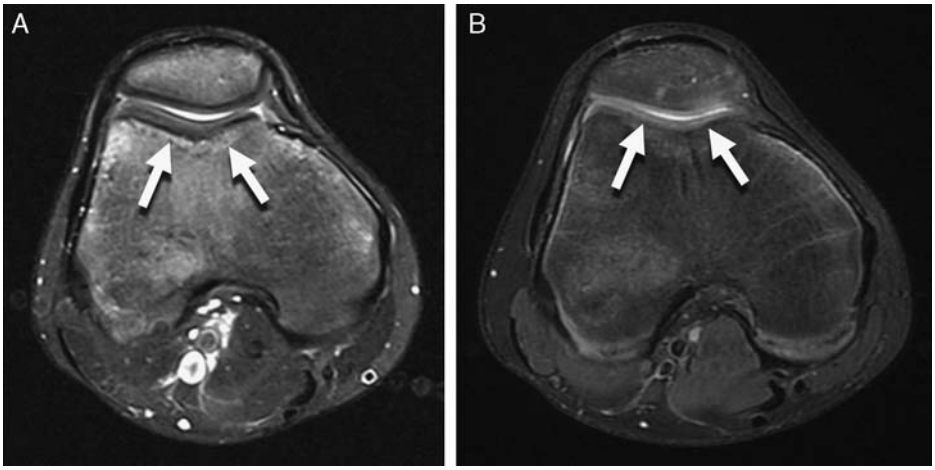

FIGURE 3. T2-weighted fast spin echo axial magnetic resonance images showing cartilage fissuring (arrows) in the trochlear groove of the knee at clinical presentation (A) and cartilage healing (arrows) 3 months after internal fixation of the trochlear osteochondritis dissecans lesion (B).

condyle.[16] Radiographs did not demonstrate the lesion in about half the cases, making MRI the diagnostic study of choice to confirm the presence of trochlear groove OCD. Six patients with trochlear groove lesions had other OCD lesions in their same knee and/or opposite knee. This high rate of multifocal involvement may support an underlying defect in the knee cartilage, suggesting a possible genetic etiology, or it may be related to high sports activity level that most patients reported.

In the largest reported series of patellofemoral OCD lesions to date,[8] 13 knees with trochlear lesions were included, all of which were on the convex articular surfaces of the trochlea and not in the concave central groove portion. Of note, they described a male-to-female ratio of 4:1, which is greater than previously reported sex differences in standard location OCD.[12] We found a similar sex disparity in patients with trochlear OCD lesions. In this prior series,[8] MRI was not performed in any patient, and neither the radiographic nor arthroscopic grade of the lesions was systematically described. Further, although a variety of treatment approaches were employed, including removal of loose bodies or loose osteochondral fragments in 12 patients, drilling was performed in only one patient, and fixation was not performed in any patients. In our study, trochlear OCD cartilage preservation with drilling and/or fixation was performed in the majority (10/16) of knees. The prior study had minimal comment on patient outcomes.[8] Although our sample size was too small and variable for statistical comparison, we report patient outcomes of radiologic healing, pain resolution, and return to sports activities.

In another case series,[1] 13 patients had only trochlear OCD lesions, all of which were seen in male patients. The author noted a relatively common clinical presentation among the cohort, which he distinguished from classic OCD symptoms. This included a gradual onset of

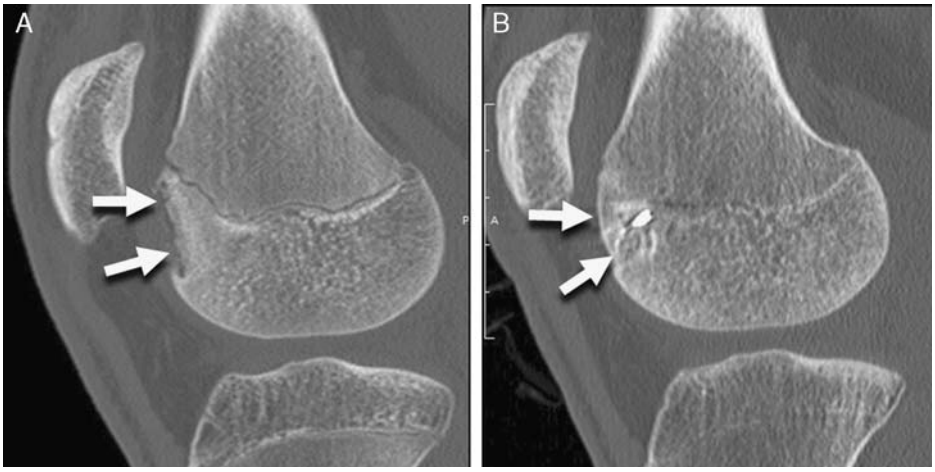

FIGURE 4. A, A preoperative computed tomography scan showing an osteochondritis dissecans lesion of the trochlear groove of the knee with minimal bone content in the lesion (arrows). B, A computed tomography scan taken 10 months postoperatively showing subchondral bone regeneration within the osteochondritis dissecans lesion (arrows).

TABLE 1. Radiographic Healing After Treatments for Trochlear Groove Osteochondritis Dissecans of the Knee Patellofemoral Joint in Adolescents

	n (%)	
	Healed	**Not Healed**
Nonoperative treatments	2 (50)	2 (50)
Activity restriction with or without cast	1 (33)	2 (67)*
Physical therapy	1 (100)	0 (0)
Nonoperative to operative treatment	1 (100)	0 (0)
Cast and activity restriction to drilling	1 (100)*	0 (0)
Operative treatments	8 (67)	4 (33)
Drilling	2 (100)	0 (0)
Fixation	3 (100)	0 (0)
Microfracture	1 (50)	1 (50)
Drilling with microfracture	1 (100)	0 (0)
Drilling with fixation	0 (0)	3 (100)
Drilling with osteochondral graft	1 (100)	0 (0)

*Same patient—failed nonoperative treatment, then went on to operative treatment.

pain, pain with running and jumping, and pain with resisted extension, specifically from 20 to 45 degrees. As in our study, treatment typically involved a combination of different surgical interventions, including nonoperative treatment, loose body removal, drilling, and fixation.

Another series[7] of all male patients with trochlear groove lesions reported articular softening in 7 knees in 5 patients. Interestingly, all were high school or college athletes (age range, 15 to 21 y), who participated in sports between 4 to 8 hours per day. Although their patients presented at an older age compared with typical juvenile OCD cases and were older than the patients in our study, 4 of 5 patients had been symptomatic for at least 2 years. The lateral trochlea was affected in 6 of the 7 knees, and a tight lateral retinaculum was noted in 4 of 5 patients, which the authors reported effectively treating with an arthroscopic lateral release, with or without drilling of the subchondral bone. They, however, did not provide radiographic healing, pain resolution, or return to sports measures to support their claim.

Readers should be aware of the limitations of our study. First, because of the rarity of trochlear groove OCD, even with patients from multiple sites, the sample size of our study limited our ability to statistically assess the effectiveness of treatments. Second, complete x-rays and MRI studies were not available for all patients, and outcomes could not be definitively evaluated for 8 knees in 6 patients, as they were still in the early stages of treatment. Third, many patients were treated with a combination of surgical techniques over time by multiple surgeons at multiple institutions, which limits our ability to draw conclusions on the effectiveness of individual treatments. Fourth, postoperative rehabilitation was not well-controlled. However, most surgeons followed the general guidelines for cartilage repair, with non–weight-bearing with full motion for the first 6 weeks after surgery, followed by physical therapy and return to sports at 3 to 4 months postoperatively depending on radiologic healing. Finally, follow-up visits were also not well-controlled, although typically patients returned 4 to 6 weeks after surgery and again 3 to 4 months after surgery. Furthermore, half of the patients had healed before 1 year, limiting our duration of follow-up.

In conclusion, trochlear groove lesions of the knee patellofemoral joint are more prevalent in males and athletes, often present in adolescents after a long period of knee symptoms, and are often overlooked on plain radiographs. This delay in diagnosis may account for higher rates of instability than those reported for other locations of OCD. Several surgical approaches, including subchondral bone drilling and internal fixation for cartilage preservation in stable lesions and primary chondral debridement and microfracture for unstable lesions, may be effective for treating trochlear groove lesions in adolescents, with approximately 67% success. To statistically compare the effectiveness of treatments, future multicenter prospective studies with larger samples, longer term follow-up, and standardization of treatment approaches are still needed. This study provides a foundation for future study on managing OCD lesions of the trochlear groove in an effort to improve the diagnosis, treatment, and healing rates of this relatively rare disorder.

REFERENCES

1. Smith JB. Osteochondritis dissecans of the trochlea of the femur. *Arthroscopy*. 1990;6:11–17.
2. Kessler JI, Nikizad H, Shea KG, et al. The demographics and epidemiology of progression of osteochondritis dissecans of the knee in children and adolescents. *Am J Sports Med*. 2014;42:320–326.
3. Chambers HG, Shea KG, Anderson AF, et al. Diagnosis and treatment of osteochondritis dissecans. *J Am Acad Orthop Surg*. 2011;19:297–306.
4. Chambers HG, Shea KG, Carey JL. AAOS Clinical Practice Guideline: diagnosis and treatment of osteochondritis dissecans. *J Am Acad Orthop Surg*. 2011;19:307–309.
5. Kurzweil PR, Zambetti GJ, Hamilton WG. Osteochondritis dissecans in the lateral patellofemoral groove. *Am J Sports Med*. 1988;16:308–310.
6. Luessenhop S, Behrens P, Bruns J, et al. Bilateral osteochondritis dissecans of the medial trochlea femoris: an unusual case of patellofemoral pain. *Knee Surg Sports Traumatol Arthrosc*. 1993;1:187–188.
7. Mori Y, Kubo M, Shimokoube J, et al. Osteochondritis dissecans of the patellofemoral groove in athletes: unusual cases of patellofemoral pain. *Knee Surg Sports Traumatol Arthrosc*. 1994;2:242–244.
8. Peters TA, McLean ID. Osteochondritis dissecans of the patellofemoral joint. *Am J Sports Med*. 2000;28:63–67.
9. Takahashi Y, Nawata K, Hashiguchi H, et al. Bilateral osteochondritis dissecans of the lateral trochlea of the femur: a case report. *Arch Orthop Trauma Surg*. 2008;128:469–472.
10. Ronga M, Zappalá G, Cherubino M, et al. Osteochondritis dissecans of the entire femoral trochlea. *Am J Sports Med*. 2006;34:1508–1511.
11. Detterline AJ, Goldstein JL, Rue JP, et al. Evaluation and treatment of osteochondritis dissecans lesions of the knee. *J Knee Surg*. 2008;21:106–115.
12. Kocher MS, Tucker R, Ganley TJ, et al. Management of osteochondritis dissecans of the knee: current concepts review. *Am J Sports Med*. 2006;34:1181–1191.
13. Crawford DC, Safran MR. Osteochondritis dissecans of the knee. *J Am Acad Orthop Surg*. 2006;14:90–100.
14. Flynn JM, Kocher MS, Ganley TJ. Osteochondritis dissecans of the knee. *J Pediatr Orthop*. 2004;24:434–443.

15. Wall E, Von Stein D. Juvenile osteochondritis dissecans. *Orthop Clin North Am*. 2003;34:341–353.
16. Wall EJ, Vourazeris J, Myer GD, et al. The healing potential of stable juvenile osteochondritis dissecans knee lesions. *J Bone Joint Surg Am*. 2008;90:2655–2664.
17. Biscarini A, Benvenuti P, Botti F, et al. Modelling the joint torques and loadings during squatting at the Smith machine. *J Sports Sci*. 2011;29:457–469.
18. Escamilla RF. Knee biomechanics of the dynamic squat exercise. *Med Sci Sports Exerc*. 2001;33:127–141.
19. Escamilla RF, Fleisig GS, Lowry TM, et al. A three-dimensional biomechanical analysis of the squat during varying stance widths. *Med Sci Sports Exerc*. 2001;33:984–998.
20. Escamilla RF, Fleisig GS, Zheng N, et al. Biomechanics of the knee during closed kinetic chain and open kinetic chain exercises. *Med Sci Sports Exerc*. 1998;30:556–569.
21. Escamilla RF, Fleisig GS, Zheng N, et al. Effects of technique variations on knee biomechanics during the squat and leg press. *Med Sci Sports Exerc*. 2001;33:1552–1566.
22. Escamilla RF, Francisco AC, Fleisig GS, et al. A three-dimensional biomechanical analysis of sumo and conventional style deadlifts. *Med Sci Sports Exerc*. 2000;32:1265–1275.
23. Escamilla RF, Zheng N, Macleod TD, et al. Patellofemoral joint force and stress between a short- and long-step forward lunge. *J Orthop Sports Phys Ther*. 2008;38:681–690.
24. Kennedy JC. Osteochondral fractures of the knee joint. In: Kennedy JC, ed. *The Injured Adolescent Knee*. Baltimore, MD: Lippincott Williams & Wilkins; 1979:103–120.
25. Aichroth P. Osteochondritis dissecans of the knee: a clinical survey. *J Bone Joint Surg Br*. 1971;53:440–447.
26. Hefti F, Beguiristain J, Krauspe R, et al. Osteochondritis dissecans: a multicenter study of the European Pediatric Orthopedic Society. *J Pediatr Orthop B*. 1999;8:231–245.
27. Edwards DH, Bentley G. Osteochondritis dissecans patellae. *J Bone Joint Surg Br*. 1977;59:58–63.
28. Marandola MS, Prietto CA. Arthroscopic Herbert screw fixation of patellar osteochondritis dissecans. *Arthroscopy*. 1993;9:214–216.
29. Matava MJ, Brown CD. Osteochondritis dissecans of the patella: arthroscopic fixation with bioabsorbable pins. *Arthroscopy*. 1997;13:124–128.
30. Rombold C. Osteochondritis dissecans of the patella: a case report. *J Bone Joint Surg*. 1936;18:230–231.
31. Schwarz C, Blazina ME, Sisto DJ, et al. The results of operative treatment of osteochondritis dissecans of the patella. *Am J Sports Med*. 1988;16:522–529.
32. Axhausen G. The origin of free bodies in the joints; their relation with arthritis deformans. *Arch F Klin Chir*. 1914;104:581–679.
33. Linden B. The incidence of osteochondritis dissecans in the condyles of the femur. *Acta Orthop Scand*. 1976;47:664–667.
34. Lindholm TS. Osteochondritis dissecans of the knee: a clinical study. *Chir Gynaecol Fenn*. 1974;63:69–76.

