Original Investigation

Magnetic Resonance Imaging of Osteochondritis Dissecans: Validation Study for the ICRS Classification System

Jutta M. Ellermann, MD, PhD, Bryan Donald, MD, Sara Rohr, Takashi Takahashi, MD, Marc Tompkins, MD, Bradley Nelson, MD, Amanda Crawford, MD, Christopher Rud, MD, Jeffrey Macalena, MD

Rationale and Objectives: In this retrospective case series, we utilize arthroscopy as the gold standard to determine if magnetic resonance imaging (MRI) of the knee can predict osteochondritis dissecans (OCD) lesion stability, the most important information to guide patient treatment decisions. It is hypothesized that the classification system of the International Cartilage Repair Society (ICRS) will allow for improved assessment of lesion grade and stability in OCD.

Materials and Methods: Routine MRI studies of 46 consecutive patients with arthroscopically proven OCD lesions (mean age: 23.7 years; 26 male, 16 female) were assessed by three radiologists who were blinded to arthroscopic results. Arthroscopic images were evaluated by two orthopedic surgeons in consensus. The OCD criteria of the ICRS were applied to arthroscopy and imaging interpretations. Inter-rater correlation statistics and accuracy of magnetic resonance (MR) grading with respect to arthroscopy were determined.

Results: Only 56% of the available MR reports assigned a label of stable or unstable to the lesion description. Of these, 58% of the lesions were deemed unstable and 42% were stable. Accuracy was 53% when reports addressed stability. Utilizing the ICRS classification system, for all three readers combined, the respective sensitivity, specificity, and accuracy of MR imaging to determine lesion stability were 70%, 81%, and 76%. When compared to the original MRI report, the overall accuracy increased from 53% to 76% when readers were given the specific criteria of the OCD ICRS classification. However, inter-reader variability remained high, with Krippendorf's alpha ranging from 0.48 to 0.57.

Conclusions: In this paper, we utilize arthroscopy as the gold standard to determine if MRI can predict OCD lesion stability, the most important information to guide patient treatment decisions. To our surprise, the analysis of the existing radiology reports that addressed stability revealed an overall accuracy in defining OCD lesion stability of about 53%. The classification system of the ICRS, created by an international multidisciplinary, multi-expert consortium, did markedly improve the accuracy, but consistency among different readers was lacking. This retrospective study on OCD reporting and classification highlights the inadequacy of existing classification schemes, and emphasizes the critical need for improved diagnostic MRI protocols in musculoskeletal radiology in order to propel it toward evidence-based medicine.

Key Words: Osteochondritis dissecans; knee; magnetic resonance imaging; grading scales.

INTRODUCTION

Osteochondritis dissecans (OCD) is the term first utilized in 1887 (1) to describe the occurrence of a progeny osteochondral fragment separated from the parent bone. The etiology remains controversial (2) considering genetic (3), traumatic (4,5), and vascular causes (6). In the knee, OCD most commonly occurs in the central aspect of the medial femoral condyle, followed by the lateral femoral condyle, the trochlea, and the patella (7). Treatment of OCD largely depends on the presence or absence of stability of the progeny and the parent bone (8,9). Surgical fixation is recommended for stable OCD lesions that have failed nonoperative management, as well as for all unstable lesions (9,10).

There is a general consensus that OCD lesion stability is determined based on both clinical and radiological examinations (11–14). Magnetic resonance imaging (MRI) has been shown to be reliable in predicting the stability of OCD once a patient's physis has closed (15). However, the same research

Acad Radiol 2016; ■:■■–■■

From the Department of Radiology, University of Minnesota, MMC 292, 420 Delaware St. SE, Minneapolis, MN 55455 (J.M.E., B.D., S.R., T.T., A.C.); Department of Orthopaedic Surgery, University of Minnesota, Minneapolis, Minnesota (M.T., B.N., C.R., J.M.). Received December 6, 2015; revised January 16, 2016; accepted January 17, 2016. **Address correspondence to:** J.M.E. e-mail: eller001@umn.edu

http://dx.doi.org/10.1016/j.acra.2016.01.015

has shown poor correlation between magnetic resonance (MR) findings and stability on arthroscopy prior to skeletal maturity (15). Another study concluded that MRI should not be used in isolation to assess lesion stability in juvenile OCD (16). Frequently, stability is not specifically assessed on preoperative imaging reports. This has left the preoperative diagnosis of stability to be heavily based on clinical rather than imaging findings (9).

There are several arthroscopic classification systems that have been used (17). The International Cartilage Repair Society (ICRS) has attempted to create a more standardized and universally accepted system (17,18). As higher grades are more likely to be unstable and need intervention, there is a utility to using a corresponding grading system in preoperative MR imaging (19).

The purpose of this study was to determine the accuracy and inter-rater variability of MR diagnosis of grade and stability of OCD in the knee as compared to the gold standard of arthroscopy using the ICRS classification system for both MRI and arthroscopic assessment. In this study, it is hypothesized that lesion grade and stability determination in OCD will be more accurate and consistent with specific assessment criteria than without.

MATERIALS AND METHODS

Study Design and Patient Selection

This study was a retrospective review of consecutive patients with OCD of the knee from November 2006 through May 2014. The study was approved by the local institutional review board and performed in accordance with the Health Insurance Portability and Accountability Act (HIPAA) guidelines. Inclusion criteria were OCD in the knee, preoperative MR imaging, and arthroscopic images and report. Exclusion criteria were prior surgery on the same knee, nondiagnostic MR images, and nondiagnostic arthroscopic images.

MR Examination

Patients underwent MR imaging at multiple clinical imaging sites, and studies were deemed to be of diagnostic quality by two board-certified radiologists (8 years and 7 years of experience, respectively) with fellowship training in musculoskeletal (MSK) radiology. All studies contained at a minimum axial, coronal, and sagittal fluid-sensitive (proton density [PD] or T2-weighted) sequences with or without fat saturation.

Several other imaging characteristics that have been associated with OCD were determined. These characteristics consist of bone marrow edema deep to the lesion, fluid signal at the interface between normal bone and the lesion, hypointense linear signal deep to the fluid signal, cartilage disruption, cartilage edema, cartilage thickening, hypointense signal in the cartilage, and overall size of the lesion (15,19–21).

TABLE 1. (A) MRI Grading of Osteochondral defects (ICRS Classification System for OCD Lesions) and (B) International Cartilage Repair Society (ICRS Classification System for OCD Lesions)

(A)
Grade 1: Thickening of cartilage without disruption
1a: Bone marrow edema
1b: Fluid at lesion–bone interface
Grade 2: Cartilage breached, fluid at interface, but not entire interface
Grade 3: Cartilage completely disrupted with fluid interface surrounding lesion
Grade 4: Displaced fragment
Dipaola et al. (1991) (19)
(B)
ICRS OCD I: Stable lesions with a continuous but softened area covered by intact cartilage
ICRS OCD II (A with intact cartilage, B cartilage lesion): lesions with partial discontinuity at the lesion and bone interface that are stable when probed
ICRS OCD III (A intact articular cartilage, B cartilage lesion): lesions with a complete discontinuity that are not yet dislocated ("dead in situ")
ICRS OCD IV: Empty defects and defects with a dislocated fragment or a loose fragment within the bed
Brittberg and Winalski (2003) (18)

MRI, magnetic resonance imaging; OCD, osteochondritis dissecans.

Following this, an overall grade and stability on MR imaging was determined by the same two board-certified radiologists with MSK fellowship training (MR readers 1 and 2), as well as an MSK radiology fellow (MR reader 3). Grading was based on previously published standards (19), as well as subcategories based on additional cartilage imaging features (Table 1A). During the collection of imaging features, and grading and determination of stability, image reviewers were blinded to the operative findings as well as to the initial MR interpretation. Additionally, a retrospective review of the MR reports was performed when report was available (34 of 42 total cases [81%]) for the presence of a grade or determination of stability.

Arthroscopic Evaluation

Two orthopedic surgeons with fellowship training and subspecialty board certification in sports medicine reviewed arthroscopy images. Through this review, an overall grade based on the ICRS arthroscopic criteria (Table 1B) and determination of the presence or absence of stability was made (18). The two surgeons reviewed each case independently. On cases where there was a discrepancy between the two interpretations (16 cases, 38%), a consensus agreement was reached between the two.

Statistical Analysis

Inter-rater correlation statistics, accuracy of MR grading with respect to the standard of arthroscopic review, and accuracy of the initial MRI reports were determined using Krippendorf's alpha.

TABLE 2. Arthroscopic Grade Distribution

ICRS OCD I	ICRS OCD IIA	ICRS OCD IIB	ICRS OCD IIIA	ICRS OCD IIIB	ICRS OCD IV
6 (52%)	1 (2%)	15 (36%)	0 (0%)	7 (17%)	13 (31%)

ICRS, International Cartilage Repair Society; OCD, osteochondritis dissecans.

RESULTS

Forty-six cases of knee OCD lesions with arthroscopy, but no prior surgery on the same knee, were compiled between November 2006 and May 2014. Two patients were excluded for inadequate MR image quality, and two patients were excluded for inadequate quality of arthroscopic images. This resulted in 42 patients being included in the study, mean age of 23.7 years (range: 10–48 years) with 26 male (62%) and 16 female (38%) patients. These 42 patients were further subdivided into adults and juveniles based on the presence of an open physis on plain radiograph; there were 14 juveniles (33%) and 28 adults (67%). The mean time span between MRI and arthroscopy was 5 months (range: <1 to 20 months).

Of the 42 OCD lesions, 29 (69%) were found in the medial femoral condyle, 9 (21%) were in the lateral femoral condyle, and 4 (10%) were in the trochlea. This distribution is consistent with previous observations of OCD in the distal femur (7).

Of the 42 patients, 22 (52%) lesions were deemed unstable on arthroscopy, whereas 20 (48%) were deemed stable. Arthroscopic grade distribution is listed in Table 2.

Using Krippendorf's alpha as a measure of agreement between MR-determined grade and the gold standard of arthroscopy, MR reader 1 had mild agreement and MR readers 2 and 3 had substantial agreement (Table 3). The prediction of stability was also found to be highly significant for readers 2 and 3, and significant for reader 1 at the 0.1 level (Table 3). There was no significant difference in agreement in the juvenile patients with respect to the adult patients. Figure 1 demonstrates a case in which none of the MR readers agreed with the arthroscopic assessment of stability, and Figure 2 demonstrates a case in which all readers were in agreement with the arthroscopic assessment.

TABLE 3. Agreement Between MR Readers and Arthroscopy

MR Reader*	Agreement of Grade (Krippendorf's Alpha)	Agreement of Stability (*P*-value)
1	0.52 [0.26–0.73]	<0.01
2	0.60 [0.37–0.77]	<0.01
3	0.68 [0.45–0.86]	0.065

MR, magnetic resonance; MSK, musculoskeletal.
Note: Numbers in brackets are 95% confidence intervals.
* MR readers 1 and 2 are board-certified radiologists with fellowship training in musculoskeletal radiology; MR reader 3 is an MSK radiology fellow.

TABLE 4. Inter-rater Agreement Between MR Readers

MR Readers*	Agreement of Grade (Krippendorf's Alpha)
1 and 2	0.52 [0.25–0.74]
1 and 3	0.48 [0.19–0.72]
2 and 3	0.57 [0.32–0.74]

MR, magnetic resonance; MSK, musculoskeletal.
Note: Numbers in brackets are 95% confidence intervals.
* MR readers 1 and 2 are board-certified radiologists with fellowship training in musculoskeletal radiology; MR reader 3 is an MSK radiology fellow.

Also using Krippendorf's alpha, there was mild agreement between all of the MR readers when compared to one another (Table 4). Lesions determined to be unstable on arthroscopy were deemed stable by reader 1 in two cases (9%), by reader 2 in five cases (23%), and by reader 3 in eight cases (36%).

When the three independent MRI readers agreed that a lesion was stable, the respective sensitivity, specificity, and accuracy of MR imaging to determine lesion stability were 70%, 81%, and 76%.

Of the 34 MR reports that were available, 19 assigned a label of stable or unstable (56%). Of these, 11 were deemed unstable (58%) and 8 were deemed stable (42%). Accuracy was 53% when reports addressed stability, yielding an overall accuracy of 29% when all reports were considered, whether or not they addressed stability.

The absence of cartilage thickening was mildly indicative of instability, with 4 of 42 patients not having thickened cartilage, and 3 of these 4 having unstable lesions. Additionally, the lack of central hypointensity in the cartilage of the lesion was indicative of instability, but only had a sensitivity of 14% as only three of the patients with unstable lesions demonstrated this characteristic.

DISCUSSION

The most important finding in the present study was that the analysis of the existing radiology reports revealed an overall low accuracy in defining OCD lesion stability of about 29% and that the ICRS classification system did markedly improve the accuracy to 76%, but consistency among different readers was lacking. Our findings are in keeping with several other publications highlighting the limited reliability of MRI imaging findings (15,16) for evidence-based patient management. Several issues are brought to light by these results, including that the MR criteria for stability are often difficult to evaluate using

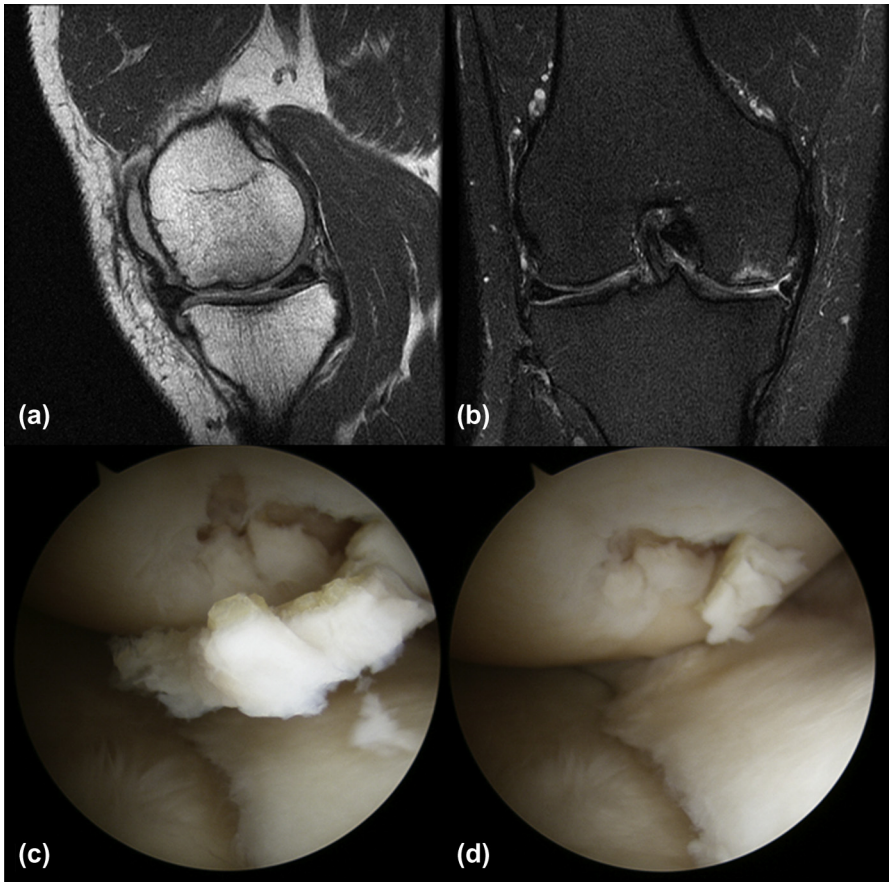

Figure 1. Osteochondritis dissecans (OCD) lesion with poor magnetic resonance (MR)–arthroscopy stability correlation with all three MR readers assessing a lesion as stable, which was subsequently found to be unstable on arthroscopy. Sagittal proton density-weighted image **(a)**, coronal T2-weighted image with fat saturation **(b)**, and arthroscopic images **(c)** and **(d)** are shown.

standard MR sequences. Specifically, the progeny bone interface is difficult to assess using current clinical MRI protocols. In addition, radiologists or other physicians reading MRs often do not address the issue of stability of osteochondral defects in their reports, and when they do accuracy is poor. Multiple causes could be hypothesized; there are no widely accepted stability criteria, or because of the above-mentioned issue of imaging sequence selection.

Because treatment of OCD largely depends on the presence or absence of stability of the progeny and the parent bone, preoperative assessment criteria for patient management decisions are based on clinical findings in combination with imaging results. Surgical fixation is recommended for stable OCD lesions that have failed nonoperative management and for all unstable lesions (9). MRI is frequently utilized to attempt differentiation of stable from unstable lesions (22), as well as to determine the severity of stable lesions and health of the fragment.

Multiple systems have been described for classifying OCD lesions of the knee on MRI and during arthroscopy (17), with varying levels of agreement and overlap among the existing classification systems. The ICRS provided a specific classification system to OCD of the knee for more standardized and universally accepted criteria with the option to transfer the arthroscopic grading into an imaging classification (18). This system consists of four arthroscopic stages of OCD lesions, which are outlined in Table 1A.

Previously, multiple MRI grading systems have also been suggested (15,16,19–21,23–26). The MRI protocols in these studies were all similar and included fat-suppressed intermediate-weighted T2-Turbo Spin Echo (TSE) or fluid-sensitive PD sequences in the sagittal and coronal plane, as well as T1-weighted TSE sequences usually in all three planes. De Smet et al. (21) first provided a well-accepted classification system, which later was refined (21,23), revealing near 100% sensitivity and specificity for unstable lesions. However, the patient cohort was small and the authors found that the hyperintense signal at the interface of the progeny and the donor site might be less specific and might not necessarily indicate instability. Kramer et al. (27) suggested the use of intra-articular gadolinium contrast agent for improved assessment of overlying articular cartilage and lesions stability. Prior studies have also found that the agreement between OCD lesion grading and stability assessment was limited in juvenile patients (15,16), whereas good agreement between MR grading of OCD and stability and the gold standard of arthroscopy was shown for adult patients. We have shown similar results with our MR readers having significant or highly significant agreement in the determination of stability utilizing the specific ICRS OCD criteria. However, inter-rater variability

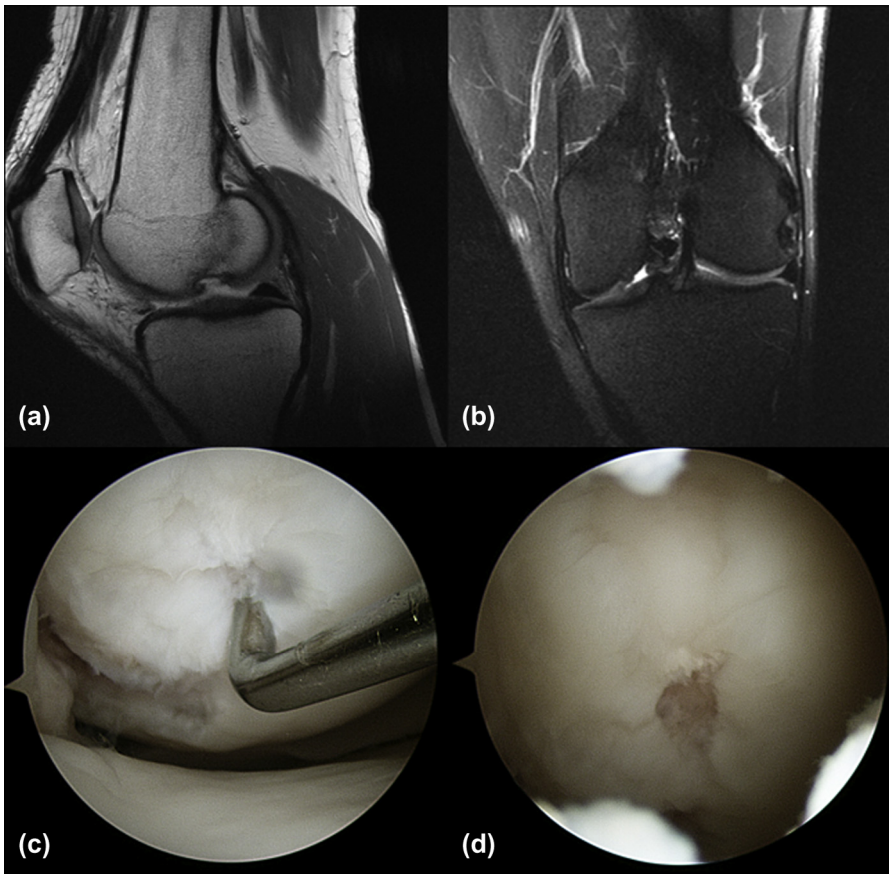

Figure 2. Osteochondritis dissecans (OCD) lesion with good magnetic resonance (MR)–arthroscopy stability correlation with all three MR readers assessing a lesion as unstable, which was subsequently proven to be unstable on arthroscopy. Sagittal proton density-weighted image **(a)**, coronal T2-weighted image with fat saturation **(b)**, and arthroscopic images **(c)** and **(d)** are shown.

remained relatively poor between the MR readers in our study. Heywood et al. (16) found in their 2010 study that MRI predicted 21 of 23 lesions to be unstable, whereas arthroscopy found only 10 of these 23 lesions to be unstable. They also determined that the most common pattern of false-positive findings involved lesions with an area of high signal intensity at the bone–fragment interface, concluding that MRI should not be used in isolation to determine lesion instability in young patients with juvenile OCD.

In addition to the standard grading of OCD, additional imaging findings of the absence of cartilage thickening and lack of central cartilage hypointensity were fairly specific for instability, but not sensitive. Given these findings, it is likely that specific sequences addressing osseous versus cartilaginous components of the OCD lesions that have been previously evaluated in animal models (28) could be more sensitive for these subtle findings, which might better elucidate their stability and health. The utilization of 3D TSE (Turbo Spin Echo) or GRE (Gradient Recalled Echo) high-resolution imaging sequences has been suggested previously (22). Also, further investigation is needed into other noninvasive findings that could indicate healing potential, such as diffusion-weighted imaging and possibly contrast-enhanced imaging to evaluate for necrotic bone and cartilage. Furthermore, identifying cartilage abnormalities using quantitative relaxation time measures could improve assessment of epiphyseal (28) as well as articular cartilage using established (29) and newer mapping methods (30).

Our study also indirectly revealed that future improvements in accuracy of lesion assessment might be limited when focusing solely on the criteria of image interpretation. Standard clinical care MRI imaging sequences are based mostly on PD, T2, and T1 TSE sequences. The respective image contrast derived from these sequences is poor in depicting bone detail and differentiating low signal intensities between osseous, fibrous, and necrotic tissues, which might become important in the future as new insights into the etiology of the disease are unfolding (5,31).

This study was limited by the retrospective nature and the relatively low sample size, some variation in image quality, finite time between imaging and arthroscopy, and the need to also retrospectively determine arthroscopic stability. Although the choice of the grading system was based on the recommendation of an expert team consensus, many other parameters have been discussed in the literature, and to this date there is no common recommendation that is considered standard of care. Additionally, the study is limited by the inherent reliance on arthroscopy to determine stability, as even the gold standard of arthroscopy has some shortcomings in that it only allows superficial visualization of the lesion (17). Particularly in grade II and grade III lesions, stability is not always readily apparent on arthroscopy.

CONCLUSIONS

In this paper, we utilize arthroscopy as the gold standard to define if MRI can predict OCD lesion stability, the most important information to guide patient treatment decisions. To our surprise, the analysis of the existing radiology reports revealed an overall accuracy in defining OCD lesion stability of about 29%. The classification system of the ICRS, created by an international multidisciplinary, multi-expert consortium, did markedly improve the accuracy, but consistency among different readers was lacking. This paper on OCD reporting and classification highlights the inadequacy of existing classification schemes and emphasizes the critical need for improved diagnostic MRI protocols in MSK radiology in order to propel it toward evidence-based medicine.

ACKNOWLEDGMENT

We thank John Hughes, PhD, from the University of Minnesota, Department of Statistics, for the statistical analysis of the data.

REFERENCES

1. König F. Über freie Körper in den Gelenken. Dtsch Z Chir 1887; 27:90–109.
2. Edmonds EW, Polousky J. A review of knowledge in osteochondritis dissecans: 123 years of minimal evolution from Konig to the ROCK study group. Clin Orthop Relat Res 2013; 471:1118–1126.
3. Bates JT, Jacobs JC, Jr, Shea KG, et al. Emerging genetic basis of osteochondritis dissecans. Clin Sports Med 2014; 33:199–220.
4. Polousky JD. Juvenile osteochondritis dissecans. Sports Med Arthrosc 2011; 19:56–63.
5. Shea KG, Jacobs JC, Jr, Grimm NL, et al. Osteochondritis dissecans development after bone contusion of the knee in the skeletally immature: a case series. Knee Surg Sports Traumatol Arthrosc 2013; 21:403–407.
6. McCoy AM, Toth F, Dolvik NI, et al. Articular osteochondrosis: a comparison of naturally-occurring human and animal disease. Osteoarthritis Cartilage 2013; 21:1638–1647.
7. Linden B. The incidence of osteochondritis dissecans in the condyles of the femur. Acta Orthop Scand 1976; 47:664–667.
8. Kocher MS, Tucker R, Ganley TJ, et al. Management of osteochondritis dissecans of the knee: current concepts review. Am J Sports Med 2006; 34:1181–1191.
9. Pascual-Garrido C, Moran CJ, Green DW, et al. Osteochondritis dissecans of the knee in children and adolescents. Curr Opin Pediatr 2013; 25:46–51.
10. Schulz JF, Chambers HG. Juvenile osteochondritis dissecans of the knee: current concepts in diagnosis and management. Instr Course Lect 2013; 62:455–467.
11. Abouassaly M, Peterson D, Salci L, et al. Surgical management of osteochondritis dissecans of the knee in the paediatric population: a systematic review addressing surgical techniques. Knee Surg Sports Traumatol Arthrosc 2013; 22:1216–1224.
12. Erickson BJ, Chalmers PN, Yanke AB, et al. Surgical management of osteochondritis dissecans of the knee. Curr Rev Musculoskelet Med 2013; 6:102–114.
13. Trinh TQ, Harris JD, Flanigan DC. Surgical management of juvenile osteochondritis dissecans of the knee. Knee Surg Sports Traumatol Arthrosc 2012; 20:2419–2429.
14. Vannini F, Battaglia M, Buda R, et al. “One step” treatment of juvenile osteochondritis dissecans in the knee: clinical results and T2 mapping characterization. Orthop Clin North Am 2012; 43:237–244, vi.
15. Kijowski R, Blankenbaker DG, Shinki K, et al. Juvenile versus adult osteochondritis dissecans of the knee: appropriate MR imaging criteria for instability. Radiology 2008; 248:571–578.
16. Heywood CS, Benke MT, Brindle K, et al. Correlation of magnetic resonance imaging to arthroscopic findings of stability in juvenile osteochondritis dissecans. Arthroscopy 2010; 27:194–199.
17. Jacobs JC, Jr, Archibald-Seiffer N, Grimm NL, et al. A review of arthroscopic classification systems for osteochondritis dissecans of the knee. Clin Sports Med 2014; 33:189–197.
18. Brittberg M, Winalski CS. Evaluation of cartilage injuries and repair. J Bone Joint Surg Am 2003; 85-A(suppl 2):58–69.
19. Dipaola JD, Nelson DW, Colville MR. Characterizing osteochondral lesions by magnetic resonance imaging. Arthroscopy 1991; 7:101–104.
20. Chen CH, Liu YS, Chou PH, et al. MR grading system of osteochondritis dissecans lesions: comparison with arthroscopy. Eur J Radiol 2013; 82:518–525.
21. De Smet AA, Ilahi OA, Graf BK. Reassessment of the MR criteria for stability of osteochondritis dissecans in the knee and ankle. Skeletal Radiol 1996; 25:159–163.
22. Zbojniewicz AM, Laor T. Imaging of osteochondritis dissecans. Clin Sports Med 2014; 33:221–250.
23. De Smet AA, Fisher DR, Graf BK, et al. Osteochondritis dissecans of the knee: value of MR imaging in determining lesion stability and the presence of articular cartilage defects. AJR Am J Roentgenol 1990; 155:549–553.
24. Mesgarzadeh M, Sapega AA, Bonakdarpour A, et al. Osteochondritis dissecans: analysis of mechanical stability with radiography, scintigraphy, and MR imaging. Radiology 1987; 165:775–780.
25. Nelson DW, DiPaola J, Colville M, et al. Osteochondritis dissecans of the talus and knee: prospective comparison of MR and arthroscopic classifications. J Comput Assist Tomogr 1990; 14:804–808.
26. Samora WP, Chevillet J, Adler B, et al. Juvenile osteochondritis dissecans of the knee: predictors of lesion stability. J Pediatr Orthop 2012; 32:1–4.
27. Kramer J, Stiglbauer R, Engel A, et al. MR contrast arthrography (MRA) in osteochondrosis dissecans. J Comput Assist Tomogr 1992; 16:254–260.
28. Toth F, Nissi MJ, Wang L, et al. Surgical induction, histological evaluation, and MRI identification of cartilage necrosis in the distal femur in goats to model early lesions of osteochondrosis. Osteoarthritis Cartilage 2015; 23:300–307.
29. Gold GE, Chen CA, Koo S, et al. Recent advances in MRI of articular cartilage. AJR Am J Roentgenol 2009; 193:628–638.
30. Ellermann J, Ling W, Nissi MJ, et al. MRI rotating frame relaxation measurements for articular cartilage assessment. Magn Reson Imaging 2013; 31:1537–1543.
31. Laor T, Zbojniewicz AM, Eismann EA, et al. Juvenile osteochondritis dissecans: is it a growth disturbance of the secondary physis of the epiphysis? AJR Am J Roentgenol 2012; 199:1121–1128.