Request # 38616031 **MAR 08, 2016**

Email (PDF) To: tbeaulieu@connecticutchildrens.org

Tina Beaulieu (CCMC)
Connecticut Childrens Medical Center
399 Farmington Ave 3rd Fl
Farmington, CT 06032

LOANSOME DOC: Journal Copy Affiliated

Title:	The Knee
Title Abbrev:	Knee
Citation:	2016 Feb 29;(). pii: S0968-0160(15)00284-7. doi: 10.1016/j.knee.2015.11.016 [Epub ahead of print]
Article:	Outcomes following impaction bone grafting for treatment of unstable osteochondritis dissecans.
Author:	Gallo RA;Plakke M;Mosher T;Black KP
NLM Unique ID:	9430798
PubMed UI:	26947463
ISSN:	0968-0160 (Print) 1873-5800 (Electronic)
Holding:	Library reports holding vol/yr
Need By:	N/A
Maximum Cost:	**$16.00**
Patron Email:	tbeaulieu@connecticutchildrens.org
Phone:	1.860.2840251
Fax:	1.860.2840367
Received:	Mar 08, 2016 (03:59 PM ET)
Lender:	University of Connecticut Health Center Library/ Farmington/ CT USA (CTUCON)

color

The Knee xxx (2015) xxx–xxx

Contents lists available at ScienceDirect

The Knee

Outcomes following impaction bone grafting for treatment of unstable osteochondritis dissecans☆,☆☆,☆☆☆,☆☆☆☆

Robert A. Gallo [a,*], Michael Plakke [b], Timothy Mosher [c], Kevin P. Black [a]

[a] Bone and Joint Institute, Department of Orthopaedics, Milton S. Hershey Medical Center, Pennsylvania State University College of Medicine, 30 Hope Drive, Hershey, PA 17033, United States
[b] Department of Anesthesia, Duke University Health System, Durham, NC, United States
[c] Department of Radiology, Milton S. Hershey Medical Center, Pennsylvania State University College of Medicine, 30 Hope Drive, Hershey, PA 17033, United States

ARTICLE INFO

Article history:
Received 29 June 2015
Received in revised form 6 November 2015
Accepted 7 November 2015
Available online xxxx

ABSTRACT

Background: Many methods have been proposed to treat unstable osteochondritis dissecans (OCD). Our purpose is to report outcomes in a cohort of patients undergoing impaction bone grafting for treatment of knee OCD.
Methods: Patients undergoing impaction bone grafting for knee OCD between 1998 and 2011 were contacted and stratified into (a) those who have undergone subsequent surgery on the affected knee and (b) those who have not had revision surgery performed on the affected knee since the impaction bone grafting procedure. For those not undergoing another procedure, physical examination, radiographs, MRI, and functional outcomes (SF12, Tegner, Activity Rating Scale, and IKDC) were obtained.
Results: Of nine patients (10 knees) undergoing the procedure, seven (eight knees) were available for follow-up. Three had revision surgery. One had debridement due to surface overgrowth and had no symptoms 43 months following debridement, while two had osteochondral allograft and autograft procedures at three and 10 years after initial surgery, respectively. Four patients did not require a revision surgical procedure at average follow-up of 55.4 months (range, 21–116 months). All had complete MRI fill of the cartilaginous defect with less than 50% of surface irregularity and redeveloped the tidemark and a heterogeneous cartilaginous surface. Follow-up Tegner, ARS, and SF12-PCS averaged 6.8, 67.5, and 56.6, respectively. All four had good/excellent IKDC results.
Conclusion: Impaction bone grafting can reliably restore osteocartilaginous defect produced by OCD and is a readily available and less-expensive option in treating OCD lesions. Further investigation is necessary to determine the long-term durability of the results.
Level IV – Case series

1. Introduction

Osteochondritis dissecans (OCD) of the knee is a disease of unknown etiology that affects the subchondral bone and articular cartilage and can lead to premature osteoarthritis [1]. While having a propensity to heal spontaneously in children and adolescents with open physes [2], OCD lesions have more ominous outcomes in adults: most do not heal spontaneously. Furthermore, unstable lesions, i.e. those with an magnetic resonance imaging (MRI)-confirmed fluid rim between the OCD lesion and the underlying bone [3], can dissociate from the native bed, produce an intra-articular loose body, and leave a crater-like defect on the weight-bearing surface of a femoral condyle. If left untreated or the free fragment excised, those with OCD are at-risk of developing early osteoarthritis [4–7].

If the fragment is of suitable quality, repair of the OCD lesion back into its native bed is often the first-line treatment [5]. However, often times the unstable piece is fragmented or lacks sufficient subchondral bone for fixation. Many surgical procedures, such as autologous chondrocyte re-implantation (ACI), osteochondral autograft transfer (OATS), and osteochondral allografts, have been proposed to remedy these difficult-to-treat lesions [9–14]. While some have shown promising short-term outcomes, few studies have reported consistent long-term success using these treatment techniques. These procedures can require multiple surgeries and can be cost-prohibitive. Furthermore, due to the amount of available autogenous cartilage, OATS may not be possible to restore the osteochondral surface created by large osteochondral defects.

Over a decade ago, the "sandwich" technique was described [15]. This two-stage procedure involved a first stage in which the OCD lesion

☆ Supported by departmental grant(s) from Milton S. Hershey Medical Center Department of Orthopaedics.
☆☆ None of the researchers or an affiliated institute has received (or agreed to receive) from a commercial entity something of value (exceeding the equivalent of US$500) related in any way to this manuscript or research.
☆☆☆ Each author certifies that his or her institution has approved the reporting of these cases, that all investigations were conducted in conformity with ethical principles of research, and that informed consent for participating in the study was obtained.
☆☆☆☆ Research was performed at the Milton S. Hershey Medical Center, Hershey, PA.
* Corresponding author at: Bone and Joint Institute, Milton S. Hershey Medical Center, Pennsylvania State University College of Medicine, 30 Hope Drive, Hershey, PA, United States. Tel.: +1 717 531 4803; fax: +1 717 531 7583.
E-mail address: rgallo@hmc.psu.edu (R.A. Gallo).

http://dx.doi.org/10.1016/j.knee.2015.11.016
0968-0160/© 2015 Elsevier B.V. All rights reserved.

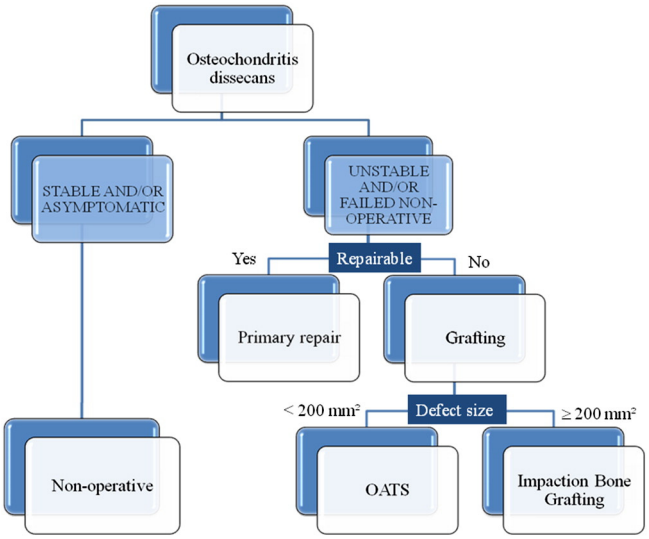

Figure 1. Our treatment algorithm for osteochondritis dissecans in skeletally mature.

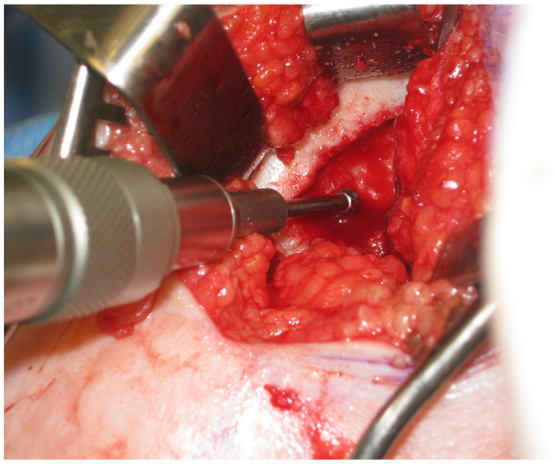

Figure 3. A high-speed burr is used to excise the sclerotic bone and create bleeding bone at the base of the lesion.

was excised, the defect was bone grafted with cancellous autograft or allograft, and chondrocytes were harvested followed by a second stage when the autologous chondrocytes were re-implanted onto the healed, bone-grafted surface. In our early experience using this technique, we observed that patients generally did subjectively so well after impaction bone grafting that they did not pursue the second-stage of treatment. The purpose of our work was to present subjective and objective results of impaction bone grafting for the treatment of unstable OCD.

2. Materials and methods

During the study period, osteochondritis dissecans in those with closed physes were treated according to the algorithm in Figure 1. Our inclusion criteria were individuals who underwent impaction bone grafting for the treatment OCD lesions measuring at least 200 mm^2. Patients with meniscal deficiency or other meniscal pathology requiring repair or partial excision in the affected knee were excluded.

3. Surgical technique

The surgical procedure is performed with the patient under general anesthesia augmented with a femoral block and supine on the operative table. A triangle is placed under the affected knee and a pneumatic tourniquet is applied to the proximal thigh but is not inflated unless necessary to improve visualization.

A medial or lateral parapatellar arthrotomy is performed to access the lesion. Once the lesion is defined, its reparability is determined. The lesion is deemed non-repairable if it is completely separated and floating, is fragmented, has insufficient subchondral bone attached to the fragment, and/or has chronic appearance with sclerotic edges. If not suitable for repair, the fragment is excised from the joint, and the native bed is defined (Figure 2). The sclerotic bone in the base of the defect is removed using a high-speed burr (Figure 3). Once the sclerotic bone has been excised and a bleeding base of bone created, a microfracture awl or K-wire is used to penetrate the base of the lesion and stimulate the influx of bone marrow elements (Figure 4). The defect is packed with cancellous autograft obtained from the proximal tibia or allograft cubes to the level of the adjacent subchondral bone (Figure 5). The bone graft is impacted into position with a tamp. Once the bone grafted has been securely tamped into position, the tourniquet is deflated and direct pressure is provided to the defect with the volar surface of the surgeon's thumb for five minutes. The bleeding that occurs into the site acts like a glue to stabilize the graft.

Post-operatively, the knee is placed into a hinged knee brace, and patient non-weightbearing for six weeks. Passive range of motion exercises and continuous passive motion six hours per day, along with four-way straight leg raises, are initiated immediately for four to six weeks.

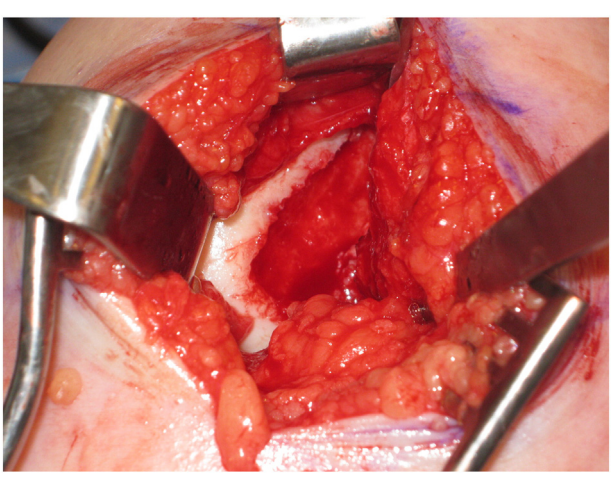

Figure 2. The edges of the defect are defined to create a well-shouldered lesion.

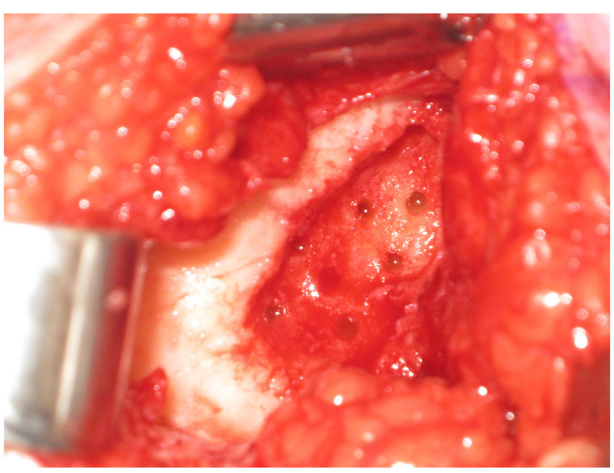

Figure 4. A microfracture awl is used to create channels at the base of lesion which facilitate egress of marrow elements into the defect.

Please cite this article as: Gallo RA, et al, Outcomes following impaction bone grafting for treatment of unstable osteochondritis dissecans, Knee (2015), http://dx.doi.org/10.1016/j.knee.2015.11.016

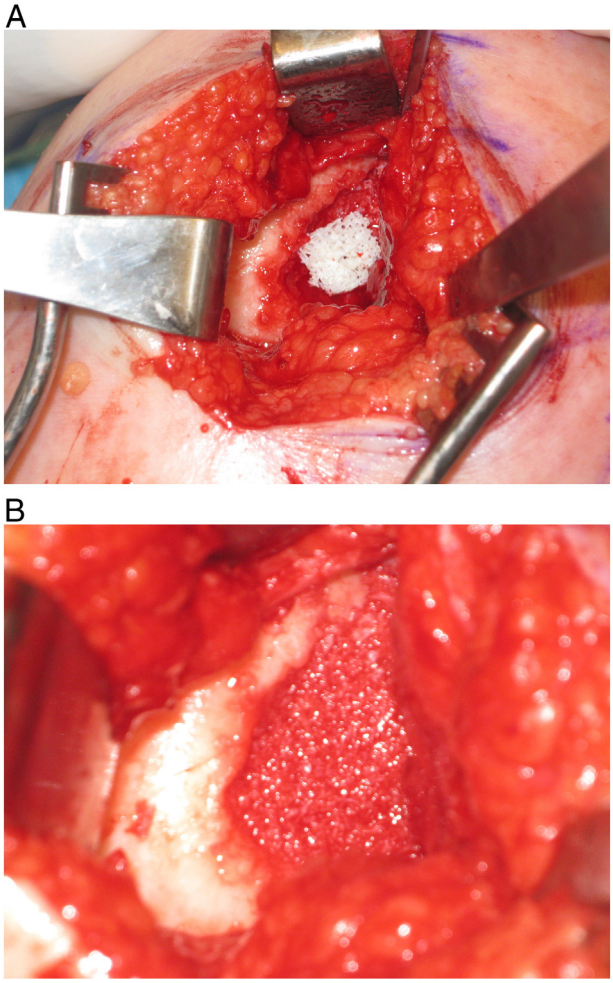

Figure 5. (a) Bone graft, either autogenous or allograft, is packed into the defect using a bone tamp. (b) The bone graft should not be above the level of the adjacent subchondral bone.

Weightbearing is permitted starting at week six and is expected to progress to full weightbearing by three months. Active-assist full flexion and low-resistance closed-chain exercises are instituted between weeks six and 11. By three months post-operatively, full weightbearing and range of motion are permitted.

4. Patient evaluation

Patients undergoing the procedure between 1998 and 2011 were retrospectively identified and contacted via telephone. Patients were stratified into two groups: (a) those who have undergone subsequent surgeries due to intra-articular pathology on the affected knee and (b) those who have not had subsequent ipsilateral knee surgery due to intra-articular pathology. Those that had an additional procedure performed on the knee were queried about the nature of the revision surgery, symptoms necessitating further treatment, and the duration of time between procedures. For those that did not have a revision procedure related to the bone grafting procedure, each patient was evaluated with (a) physical examination, (b) radiographic imaging, (c) cartilage-specific magnetic resonance imaging, and (d) functional outcome scores, including SF12 Physical and Mental, pre- and post-operative Tegner scores, Marx activity rating, International Knee Documentation Committee (IKDC) score, and knee outcome survey. Radiographic images were obtained in Anteroposterior (AP) (weightbearing), lateral, and tunnel views, and evaluated for the presence of bony healing and progression of arthritis. MRI sequences captured included coronal proton-density, sagittal and axial proton-density fat-suppression, sagittal T2 fat-suppression, sagittal T1, coronal T2, T1 mapping FLIP 1 and FLIP 2, and T2 mapping. The repair tissue was analyzed on the MRI sequences using the magnetic resonance observation of cartilage repair tissue (MOCART) scoring system as a guide [16,17].

5. Results

A total of 10 knees in nine patients underwent impaction bone grafting at our institution during the study period. Among the seven patients (eight knees) that were successfully contacted and available for follow-up, there were three females and four males. The average age of these seven at the time of the procedure was 24.1 years (range, 12–43 years). Pre-operative lesion characteristics are outlined in Table 1. All but one of the patients were bone grafted using allograft. Due to conversion of medical records to electronic version at our institution during this time period, pre-operative images that could be accurately measured for lesion size were not available for one of the patients that ultimately required a revision procedure.

Overall, 75% did not require a revision cartilage restoration procedure. At two years, no patient required cartilage restoration procedure to revise impaction bone grafting. By five years, 75% of patients had no further cartilage restoration procedures.

Five knees in four patients (average age 22.0 years, range 14–43 years) did not require a revision surgical procedure at an average follow-up of 55.4 months (range, 21–116 months). One patient, who had bilateral impaction bone grafting procedures four years apart, underwent a concomitant tibial tubercle osteotomy and had symptomatic hardware removed one year following her initial surgery. She has not required any additional procedures in the affected knee over the past eight years. All four patients denied pain or functional limitations with the knee, and all had knee range of motion symmetric to the contralateral limb. Functional scores are reported in Table 2. Follow-up radiographs demonstrated graft incorporation without evidence of osteoarthritic progression. Magnetic resonance imaging was consistent among the four patients (Figure 6) and revealed reparative tissue with the following characteristics: 100% defect fill, less than 50% integration to border zone, less than 50% surface defect, nonhomogeneous and hypointense signal, and recapitulation of the subchondral tidemark.

Three patients (average age 27.7, range 12–40 years) underwent secondary procedures. One patient, who was age 12 years at the time of the procedure and underwent autografting, won state titles in the 100-meter and 200-meter running events five years post-grafting procedure and finished in the NCAA's top 15 in the 400-meter running event seven years post-grafting procedure. However, she experienced a pop and sharp pain while sprinting and eventually underwent an OATS procedure 10 years after impaction bone grafting. Another patient gradually developed pain and increasing mechanical symptoms after impaction grafting. Further imaging demonstrated overgrowth of the graft. She ultimately underwent arthroscopic

Table 1
Pre-operative lesion characteristics.

Age	Gender	Physes	Location	AP size (mm)	Lateral size (mm)	Lesion contour
12	*F*	*Closed*	*Anterior, MFC*	*Unavailable*	*Unavailable*	*Convex*
40	*F*	*Closed*	*Anterior, MFC*	*23.5 × 6.4*	*32.3 × 8.0*	*Concave*
31	M	Closed	*Anterior, MFC*	22.4 × 4.6	35.4 × 11.4	Linear
43	M	Closed	Posterior, MFC	17.7 × 4.8	19.7 × 4.4	Convex
18	M	Closed	Anterior, MFC	20.7 × 8.1	29.8 × 12.4	Linear
14*	F	Closing	Anterior, LFC	16.2 × 9.5	22.2 × 6.7	Linear
18*	F	Closed	Anterior, LFC	21.0 × 6.5	23.1 × 4.7	Linear
17	M	Closing	Anterior, MFC	20.1 × 3.6	22.5 × 9.0	Concave

Italics = those eventually requiring revision surgery.
• = This patient underwent bilateral impaction bone grafting four years apart.
MFC = medial femoral condyle, LFC = lateral femoral condyle.

Please cite this article as: Gallo RA, et al, Outcomes following impaction bone grafting for treatment of unstable osteochondritis dissecans, Knee (2015), http://dx.doi.org/10.1016/j.knee.2015.11.016

Table 2
Functional outcomes of patients not requiring revision surgery.

Functional parameter	Average score (range)
IKDC score	92.6 (83.9–96.6)
Knee outcome score — ADL	99.38 (97.5–100)
Tegner	Pre-op 7.0 (3–9)
	Post-op 6.75 (3–9)
Marx activity rating	67.5 (60–85)
SF12-Physical	56.6 (55.3–57.8)
SF12-Mental	59.1 (57.1–60.8)

debridement of the lesion 15 months following impaction grafting and reported no knee pain at most recent follow-up, 43 months later. The third patient developed

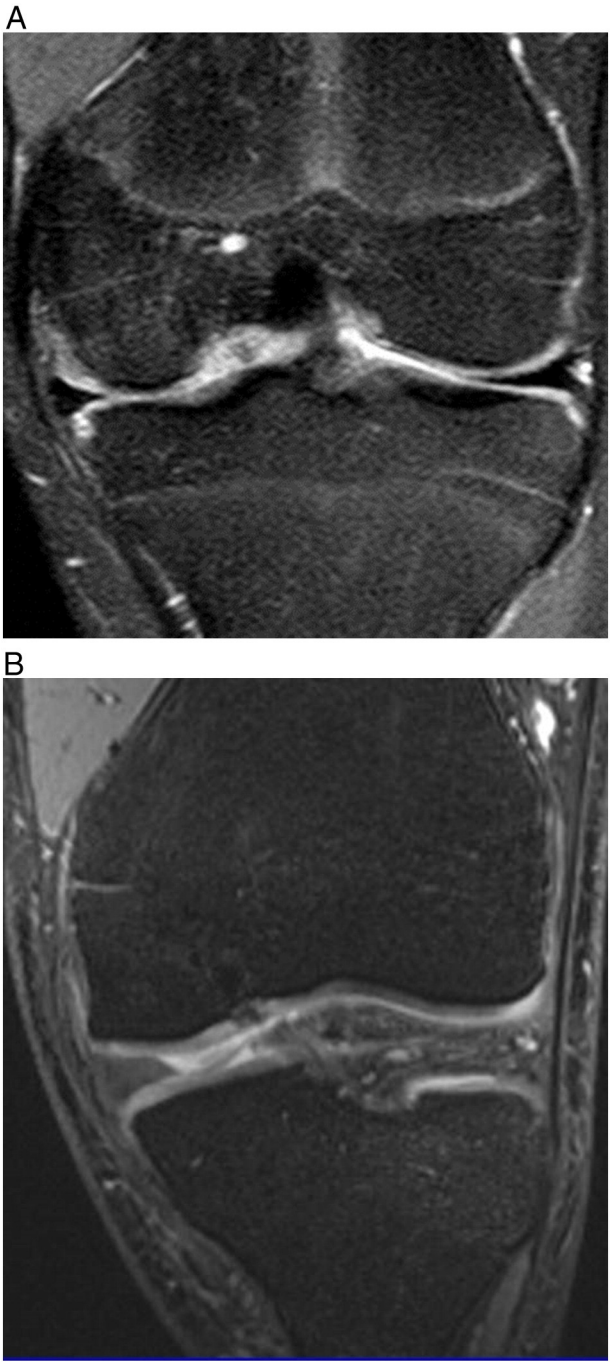

Figure 6. (a) Pre-operative MRI demonstrates unstable OCD lesion of the medial femoral condyle. (b) At 31 months post-op, the lesion demonstrates recapitulation of the tidemark and complete defect filling with a heterogeneous surface layer.

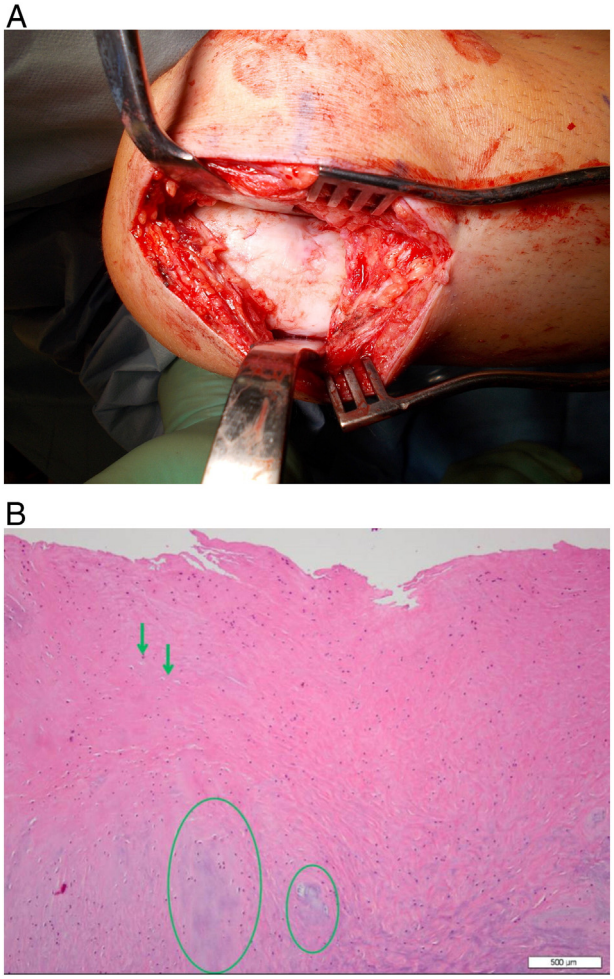

Figure 7. (a) Intra-operatively, the defect was filled with a layer of overlying surface fibrocartilage. (b) Histological sections using H&E staining confirms a surface layer of fibrocartilage with small cells within lacunae (arrows) and predominantly fibrous matrix, and a few areas of more blue hyaline type matrix (circle).

pain that steadily progressed after sporting activities and intensified at 31 months post-operatively. During subsequent work-up, long-length standing films demonstrated varus malalignment. At 35 months, he underwent osteochondral allograft but refused to have an osteotomy. Intra-operative evaluation and histological sections of the reparative tissue demonstrated fibrocartilaginous layer of tissue overlying the articular surface of the impacted bone graft (Figure 7).

6. Discussion

In our cohort, impaction bone grafting of the defect produced acceptable results in an OCD population that can be difficult to treat. While three patients required revision surgery within the follow-up period, one had over 10 years of normal function and achieved a high level of athletic success, while two others had readily identifiable causes of initial failure, which included unaddressed malalignment and overgrowth of the cartilaginous layer. The latter patient did not report pain in the ensuing 43 months after the overgrown cartilage was debrided. Over-packing the defect can result in overgrowth of the fibrocartilaginous layer (Figure 8) and should be avoided. Four other patients had excellent subjective and objective clinical outcomes and imaging studies that consistently demonstrated fill of the defect and reconstitution of the surface with a layer of fibrocartilage.

The idea of excision of the OCD and impaction bone grafting of the defect is not a novel concept. Johnson et al., recently presented a similar cohort of patients that underwent impaction bone grafting of OCD

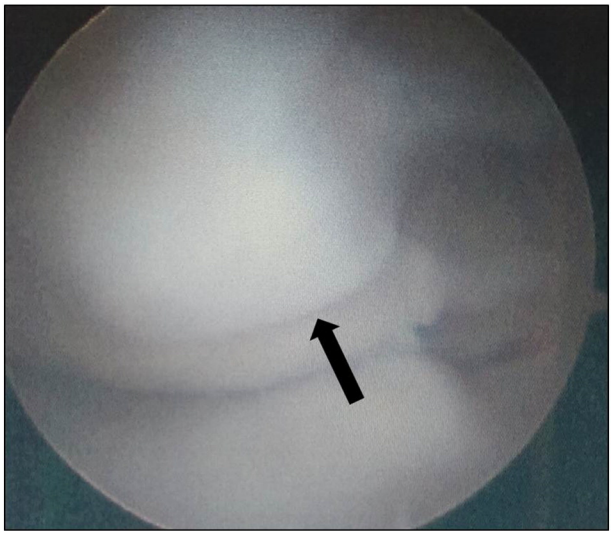

Figure 8. Overgrowth of the resultant surface fibrocartilage layer (black arrow) can occur with excessive packing of bone graft above the adjacent subchondral bone.

lesions [18]. In contrast to our study, only autograft was used to fill the defect. In this series of 52 patients which included those with OCD and osteonecrosis, 25 were available between 12 and 21 years following the procedure. OCD patients fared better than those with osteonecrosis and none of the OCD patients were asymptomatic at any time following the procedure. Similar to our study, biopsy showed initial surface fibrocartilage; however, in longer follow-up, this tissue transformed to a combination of hyaline and fibrocartilage.

While the first few patients in our cohort were initially slated for a two-stage "sandwich" procedure using ACI, none of these patients (or any other at our institution) elected to proceed with the second stage of the procedure. Studies assessing outcomes of those undergoing autologous chondrocyte reimplantation after bone grafting for OCD lesions have not shown dramatic improvements in function compared to our cohort at similar follow-up periods [9,11]. Filardo et al., and Steinhagen et al., reported IKDC scores of 81 at 72 months and 70.29 at 36 months follow-up, respectively. While studies have shown that re-created hyaline cartilage surfaces are more durable and produce better long-term outcomes than fibrocartilage, these studies were demonstrated in chondral defects and may not be applicable to OCD lesions [19].

Over the past decade, there has been an explosion of products to the market that promote restoration of articular cartilage and eliminate the need for a second procedure. Often, these products are costly and have limited shelf lives. While many of these studies report excellent clinical outcomes [20–27], few demonstrate reconstitution of the surface layer consisting entirely of hyaline cartilage [24] and none have reported mid- and long-term results in OCD cohort.

Osteochondral allografts and OATS have become a popular option to treat unstable OCD lesions in a single stage. Accumulated data suggests promising short-term and mid-term outcomes of osteochondral grafts in the OCD population [8,10,12,13]. While both grafts are inserted in a single-stage and have propensity to anatomically reconstitute the native surface anatomy and restore a hyaline cartilage surface, each procedure has its limitations. Osteochondral autografts are limited by the size of the lesion, usually lesion less than two square centimeters, and potential of donor-site morbidity, while the high cost and limited availability of osteochondral allografts can be prohibitive [28,29]. Potential for disease transmission and unknown viability of the implanted chondrocytes are other concerns in the use of osteochondral allografts [30–33].

Financial cost remains a major concern for procedures aimed at restoring articular cartilage. Using a national private insurance database, a recent study reviewed the per-patient average charges for commonly performed cartilage restoration procedures [34]. The per-patient average charges based on American Medical Association Common Procedural Technology (CPT) codes were $6110 for OATS (code 27416 or 29866), $6671 for osteochondral allograft (code 27415 or 29867), and $10,195 for ACI (code 27412 co-coded with 29870). These costs do not reflect the cost of the osteochondral allograft or the in vitro cell expansion required for ACI. An osteochondral allograft can be purchased for roughly $10,950 [35], while ACI can cost over $66,000 [36]. Conversely, cancellous allograft cubes can be bought for $425 [37]. Given this information combined with the clinical data, excision of the fragment and impaction bone grafting is attractive, less expensive option for managing unstable OCD lesions.

There are many weaknesses that impair the impact of this study. Small sample size, variable and relatively short follow-up periods, and retrospective data collection limit the information available for comparison between groups within the study. Therefore, no determination of the characteristics likely to portend a poor prognosis following this procedure can be made based on the results of this study. For the same reasons, comparisons to previously reported cohorts of other surgical treatments for OCD lesions are limited. Due to the relative scarcity of this disease in most practices, multi-center studies are necessary to further answer these questions. Further study is also needed to determine the durability of the fibrocartilaginous layer produced and the long-term outcome of those undergoing impaction bone grafting. However, the study by Johnson et al., demonstrated that this surface layer undergoes further maturation and is durable up to 28 years after the initial surgery [18].

7. Conclusion

While this study does have its limitations, excision of the unstable OCD fragment and impaction bone grafting of the defect can have predictable results that are comparable to other options, which are far more costly. In an era of increasing scrutiny of health care expenditures, we believe that surgeons should consider excision of the unstable fragment and impaction bone grafting of the defect in the treatment armamentarium of unstable OCD lesions. This technique continues to be our primary surgical treatment for the treatment of unstable OCD lesions of the knee.

Conflict of interest statement

While we received financial support from a departmental grant to complete this study, none of the authors have received financial support related to this study. Drs. Plakke, Mosher, and Black have no commercial or other relationships to disclose that may represent a conflict of interest. Dr. Gallo receives departmental research support from Aesculap related to a Phase III United States Food and Drug Administration clinical trial. The clinical trial investigates the efficacy of a novel collagen scaffold, which is not indicated for osteochondritis dissecans.

Acknowledgment

Funding was obtained from a departmental grant from Milton Hershey Medical Center (Grant #ORIG 941-33HY-1940) Department of Orthopaedics.

References

[1] Edmonds EW, Shea KG. Osteochondritis dissecans: editorial comment. Clin Orthop Relat Res Apr 2013;471(4):1105–6.
[2] Wall EJ, Vourazeris J, Myer GD, Emery KH, Divine JG, Nick TG, et al. The healing potential of stable juvenile osteochondritis dissecans knee lesions. J Bone Joint Surg Am Dec 2008;90(12):2655–64.
[3] De Smet AA, Ilahi OA, Graf BK. Reassessment of the MR criteria for stability of osteochondritis dissecans in the knee and ankle. Skeletal Radiol 1996;25(2):159–63.

Please cite this article as: Gallo RA, et al, Outcomes following impaction bone grafting for treatment of unstable osteochondritis dissecans, Knee (2015), http://dx.doi.org/10.1016/j.knee.2015.11.016

[4] Wright RW, McLean M, Matava MJ, Shively RA. Osteochondritis dissecans of the knee: long-term results of excision of the fragment. Clin Orthop Relat Res Jul 2004;424:239–43.
[5] Anderson AF, Pagnani MJ. Osteochondritis dissecans of the femoral condyles. Long-term results of excision of the fragment. Am J Sports Med 1997;25:830–4.
[6] Twyman RS, Desai K, Aichroth PM. Osteochondritis dissecans of the knee. A long-term study. J Bone Joint Surg Br May 1991;73(3):461–4.
[7] Linden B. Osteochondritis dissecans of the femoral condyles: a long-term follow-up study. J Bone Joint Surg Am Sep 1977;59(6):769–76.
[8] Lyon R, Nissen C, Liu XC, Curtin B. Can fresh osteochondral allografts restore function in juveniles with osteochondritis dissecans of the knee? Clin Orthop Relat Res Apr 2013;471(4):1166–73.
[9] Filardo G, Kon E, Berruto M, Di Martino A, Patella S, Marcheggiani Muccioli GM, et al. Arthroscopic second generation autologous chondrocytes implantation associated with bone grafting for the treatment of knee osteochondritis dissecans: results at 6 years. Knee Oct 2012;19(5):658–63.
[10] Sasaki K, Matsumoto T, Matsushita T, Kubo S, Ishida K, Tei K, et al. Osteochondral autograft transplantation for juvenile osteochondritis dissecans of the knee: a series of twelve cases. Int Orthop Nov 2012;36(11):2243–8.
[11] Steinhagen J, Bruns J, Deuretzbacher G, Ruether W, Fuerst M, Niggemeyer O. Treatment of osteochondritis dissecans of the femoral condyle with autologous bone grafts and matrix-supported autologous chondrocytes. Int Orthop 2010 Aug;34(6):819–25.
[12] Gudas R, Simonaityte R, Cekanauskas E, Tamosiūnas R. A prospective, randomized clinical study of osteochondral autologous transplantation versus microfracture for the treatment of osteochondritis dissecans in the knee joint in children. J Pediatr Orthop Oct-Nov 2009;29(7):741–8.
[13] Emmerson BC, Görtz S, Jamali AA, Chung C, Amiel D, Bugbee WD. Fresh osteochondral allografting in the treatment of osteochondritis dissecans of the femoral condyle. Am J Sports Med Jun 2007;35(6):907–14.
[14] Garrett JC. Fresh osteochondral allografts for treatment of articular defects in osteochondritis dissecans of the lateral femoral condyle in adults. Clin Orthop Relat Res Jun 1994;303:33–7.
[15] Bartlett W, Gooding CR, Carrington RW, Skinner JA, Briggs TW, Bentley G. Autologous chondrocyte implantation at the knee using a bilayer collagen membrane with bone graft. A preliminary report. J Bone Joint Surg Br Mar 2005;87(3):330–2.
[16] Marlovits S, Singer P, Zeller P, Mandl I, Haller J, Trattnig S. Magnetic resonance observation of cartilage repair tissue (MOCART) for the evaluation of autologous chondrocyte transplantation: determination of interobserver variability and correlation to clinical outcome after 2 years. Eur J Radiol Jan 2006;57(1):16–23.
[17] Marlovits S, Striessnig G, Resinger CT, Aldrian SM, Vecsei V, Imhof H, et al. Definition of pertinent parameters for the evaluation of articular cartilage repair tissue with high-resolution magnetic resonance imaging. Eur J Radiol Dec 2004;52(3):310–9.
[18] Johnson LL, Delano M, Spector M, Pittsley A, Gottschalk A. The long-term clinical outcomes following autogenous bone grafting for large-volume defects of the knee. 12- to 21-year follow-up. Cartilage Apr 2014;5(2):86–96.
[19] Moriya T, Wada Y, Watanabe A, Sasho T, Nakagawa K, Mainil-Varlet P, et al. Evaluation of reparative cartilage after autologous chondrocyte implantation for osteochondritis dissecans: histology, biochemistry, and MR imaging. J Orthop Sci May 2007;12(3):265–73.
[20] Verdonk P, Dhollander A, Almqvist KF, Verdonk R, Victor J. Treatment of osteochondral lesions in the knee using a cell-free scaffold. Bone Joint J Mar 2015;97B(3):318–23.
[21] Delcogliano M, Menghi A, Placella G, Speziali A, Cerulli G, Pasqualotto S, et al. Treatment of osteochondritis dissecans of the knee with a biomimetic scaffold. A prospective multicenter study. Joints Aug 1 2014;2(3):102–8.
[22] Berruto M, Delcogliano M, de Caro F, Carimati G, Uboldi F, Ferrua P, et al. Treatment of large knee osteochondral lesions with a biomimetic scaffold: results of a multicenter study of 49 patients at 2-year follow-up. Am J Sports Med Jul 2014;42(7):1607–17.
[23] Delcogliano M, de Caro F, Scaravella E, Ziveri G, De Biase CF, Marotta D, et al. Use of innovative biomimetic scaffold in the treatment for large osteochondral lesions of the knee. Knee Surg Sports Traumatol Arthrosc Jun 2014;22(6):1260–9.
[24] Farr J, Tabet SK, Margerrison E, Cole BJ. Clinical, radiographic, and histological outcomes after cartilage repair with particulated juvenile articular cartilage: a 2-year prospective study. Am J Sports Med Apr 9 2014;42(6):1417–25.
[25] Tompkins M, Hamann JC, Diduch DR, Bonner KF, Hart JM, Gwathmey FW, et al. Preliminary results of a novel single-stage cartilage restoration technique: particulated juvenile articular cartilage allograft for chondral defects of the patella. Arthroscopy Oct 2013;29(10):1661–70.
[26] Filardo G, Kon E, DiMartino A, Busacca M, Altadonna G, Marcacci M. Treatment of knee osteochondritis dissecans with a cell-free biomimetic osteochondral scaffold: clinical and imaging evaluation at 2-year follow-up. Am J Sports Med Aug 4 2013;41(8):1786–93.
[27] Farr J, Cole BJ, Sherman S, Karas V. Particulated articular cartilage: CAIS and DeNovo NT. J Knee Surg 2012 Mar;25(1):23–9.
[28] De Caro F, Bisicchia S, Amendola A, Ding L. Large fresh osteochondral allografts of the knee: a systematic clinical and basic science review of the literature. Arthroscopy Feb 3 2015(14). http://dx.doi.org/10.1016/j.arthro.2014.11.025 ([Epub ahead of print] pii: S0749-8063 00943-8).
[29] Bedi A, Feeley BT, Williams 3rd RJ. Management of articular cartilage defects of the knee. J Bone Joint Surg Am Apr 2010;92(4):994–1009.
[30] Pallante AL, Chen AC, Ball ST, Amiel D, Masuda K, Sah RL, et al. The in vivo performance of osteochondral allografts in the goat is diminished with extended storage and decreased cartilage cellularity. Am J Sports Med Aug 2012;40(8):1814–23.
[31] Pallante AL, Bae WC, Chen AC, Görtz S, Bugbee WD, Sah RL. Chondrocyte viability is higher after prolonged storage at 37 degrees C than at 4 degrees C for osteochondral grafts. Am J Sports Med Nov 2009;37(Suppl. 1):24S–32S.
[32] Kim HT, Teng MS, Dang AC. Chondrocyte apoptosis: implications for osteochondral allograft transplantation. Clin Orthop Relat Res Aug 2008;466(8):1819–25.
[33] Williams SK, Amiel D, Ball ST, Allen RT, Wong VW, Chen AC, et al. Prolonged storage effects on the articular cartilage of fresh human osteochondral allografts. J Bone Joint Surg Am Nov 2003;85-A(11):2111–20.
[34] Zhang JY, Cohen JR, Wang JC, Petrigliano FA, McCallister DR, Jones KJ. The costs associated with the perioperative management and treatment of articular cartilage lesions of the knee. American Academy of Orthopaedic Surgeons, Annual Meeting, Las Vegas, NV, March 24–27; 2015.
[35] Allosource. Personal communication; October 2012.
[36] Samuelson EM, Brown DE. Cost-effectiveness analysis of autologous chondrocyte implantation: a comparison of periosteal patch versus type I/III collagen membrane. Am J Sports Med 2012 Jun;40(6):1252–8.
[37] Integra. Personal communication; October 2012.

Please cite this article as: Gallo RA, et al, Outcomes following impaction bone grafting for treatment of unstable osteochondritis dissecans, Knee (2015), http://dx.doi.org/10.1016/j.knee.2015.11.016